

Biologic width around titanium implants. A physiologically formed and stable dimension over time

Hermann JS, Buser D, Schenk RK, Higginbottom FL, Cochran DL. Biologic width around titanium implants. A physiologically formed and stable dimension over time. Clin Oral Impl Res 2000; 11: 1–11. © Munksgaard 2000.

Research in implant dentistry has mainly focused on hard tissue integration with much less data available with regards to soft tissue integration involving epithelium and connective tissue. In the present study, the implantogingival junction of unloaded and loaded non-submerged titanium implants has been analyzed histometrically in the canine mandible. In 6 foxhounds, 69 implants were placed. Dogs in the unloaded group were sacrificed 3 months after implant placement. Loaded implants were restored with gold crowns and those dogs were sacrificed after 3 months and 12 months of loading. Non-decalcified histologic sections were analyzed histometrically measuring the dimensions of the Sulcus Depth (SD), the Junctional Epithelium (JE), and the Connective Tissue Contact (CTC). Histometric evaluation revealed that significant changes within tissue compartments (SD, JE, CTC) occurred over time ($P < 0.05$). Sulcus Depth had a mean of 0.49 mm and 0.50 mm after 3 months and 6 months of healing, but after 15 months was 0.16 mm which was significantly different. Similarly, the length of the Junctional Epithelium after 3 months and 6 months of healing was 1.16 mm and 1.44 mm, respectively, and these values were significantly different from measurements taken after 15 months (1.88 mm). The area of Connective Tissue Contact showed a different pattern of change in that after 3 months of healing (1.36 mm) it was significantly different from the same area after 6 months and 15 months which were 1.01 mm and 1.05 mm, respectively. Interestingly, the sum of SD, JE, and CTC, forming the Biologic Width, did not change over the observation period ($P > 0.05$). These data indicate that the Biologic Width is a physiologically formed and stable structure over time in the case of non-submerged, one-piece titanium implants as evaluated histometrically under unloaded and loaded conditions. Dynamic changes did occur, however, within the overall Biologic Width dimension. Thus, the use of non-submerged, one-piece implants allow for stable overall peri-implant soft tissues as evaluated under loaded conditions for up to 12 months.

Joachim S. Hermann^{1,2},
Daniel Buser³,
Robert K. Schenk^{3,4},
Frank L. Higginbottom⁵,
David L. Cochran¹

¹Department of Periodontics, University of Texas Health Science Center at San Antonio, Texas, USA; ²Department of Prosthodontics, University of Basel Dental School, Switzerland; ³Department of Oral Surgery, University of Bern School of Dental Medicine, Switzerland; ⁴Institute of Pathophysiology, University of Bern, Switzerland; ⁵Department of Oral and Maxillofacial Surgery and Pharmacology, Baylor College of Dentistry, Dallas, Texas, USA

Key words: animal study – titanium implants – endosseous – unloaded – loaded – soft tissue – histometry – biologic width – esthetics

David L. Cochran, The University of Texas Health Science Center at San Antonio, Dental School, Department of Periodontics, 7703 Floyd Curl Drive, San Antonio, TX 78284-7894, USA
Tel.: +1 210 567 3600
Fax: +1 210 567 6299
e-mail: Cochran@uthscsa.edu

Accepted for publication 10 January 1999

Many clinical studies on various clinical indications have documented high success rates of endosseous dental implant therapy (Brånemark et al. 1977; Adell et al. 1981; Babbush et al. 1986; Cox & Zarb 1987; Adell et al. 1990; Buser et al. 1990; ten Bruggenkate et al. 1990; Buser et al. 1991; Behneke et al. 1992; Schmitt & Zarb 1993; Mericske-Stern et al. 1994; Jemt & Lekholm 1995; Henry et al.

1996; Buser et al. 1997). When success has been evaluated in these studies, specific criteria have been met. Generally, these criteria include lack of mobility, absence of persistent infection or discomfort, lack of pain, and absence of continuous periapical radiolucency (Albrektsson et al. 1986; Smith & Zarb 1989; Buser et al. 1990). Most of these criteria are designed to evaluate the integrity

of the bony integration of the implant and provide little information related to the soft tissue integration of the implant. Historically, this has occurred due to the popularity of the submerged approach to the placement of implants. Schroeder et al. in the later 1970s and early 1980s reported on a non-submerged approach to dental implant placement and described the soft tissue attachment/contact to the transgingival portion of the implant (Schroeder et al. 1976; Schroeder et al. 1978; Schroeder et al. 1981). It is now recognized that the non-submerged technique is as predictable as the submerged approach (Babbush et al. 1986; Buser et al. 1990; ten Bruggenkate et al. 1990; Buser et al. 1991; Gotfredsen et al. 1991; Behneke et al. 1992; Mericske-Stern et al. 1994; Buser et al. 1997; Buser et al. 1999), and in fact has advantages over the submerged approach to implant placement including: 1) the lack of an interface/microgap between the implant and abutment at or below the alveolar crest level, 2) lack of a second surgical procedure to connect a transgingival component to the top of the implant, 3) a more mature soft tissue healing due to the lack of a second-stage surgery, and, 4) a smaller crown-to-implant ratio for one-piece designed non-submerged implants. Recognizing these advantages, clinicians utilizing typically submerged implants began connecting an abutment to the implant at the time of implant placement. This technique avoids a "second stage" surgery, but results in a two-piece, but non-submerged implant (Ericsson et al. 1994; Bernard et al. 1995; Ericsson et al. 1996; Becker et al. 1997; Collaert et al. 1998).

The placement of submerged implants in a non-submerged approach has direct implications for crestal bone levels around implants and subsequently may influence the overlying soft tissues.




Fig. 1. Scanning electron micrograph of a relatively smooth, machined surface (bar=10 μm ; original magnification $\times 900$). Profilometric analysis results in an Ra value of approximately 0.15 μm and an S value of 9.6 μm .

Hermann et al. (1997) demonstrated that radiographic bone levels around non-submerged, one-piece implants do not significantly change over 6 months in the canine mandible. However, if a submerged implant with attached abutment (with an interface) is placed in either a non-submerged approach or in a submerged approach (with an abutment placed after a 3-month healing period) similar amounts of bone loss occur. This data, combined with the fact that bone loss decreased as the interface was moved coronally and the bone loss increased with the more apical placement of the interface, indicates that there is a physiologic reaction to the presence of an interface. The reason for this reaction to the interface is unknown, but may be related to the presence of microbial contamination (Quirynen & van Steenberghe 1993; Persson et al. 1996; Jansen et al. 1997) or micro-movement of the interface between the implant and the abutment or secondary implant components.

Cochran et al. (1997) documented the soft tissue dimensions and described the Biologic Width around non-submerged, one-piece dental implants. This study supported previous reports on soft tissues around non-submerged, one-piece dental implants (Buser et al. 1989; Buser et al. 1992; Listgarten et al. 1992; Romanos et al. 1995; Tonetti et al. 1995; Abrahamsson et al. 1996; Hämmerle et al. 1996; Weber et al. 1996; Piattelli et al. 1997) and showed that an area of epithelial attachment with the implant surface occurs similar in morphology to that which is found around natural teeth. In addition, an area of Connective Tissue Contact was found between the apical extension of the Junctional Epithelium and the alveolar bone comprising the first bone-to-implant contact. The dimensions of these tissues, the Biologic Width, for non-submerged, one-piece implants were demonstrated to be similar to the dimensions for the same tissues described for natural teeth (Gargiulo et al. 1961; Vacek et al. 1994).

The aim of the present study was to describe the changes in the dimensions of the Sulcus Depth, length of the Junctional Epithelium, and the area of Connective Tissue Contact over a healing period of 3 to 15 months. Significantly, for implants followed from 6 to 15 months, the implants had been restored with gold crowns. Thus, loaded implants were evaluated histologically after 3 and 12 months of function.

Materials and methods

Study animals and implants

In this study, 6 male, lab-bred American foxhounds were used. These animals were, at the be-

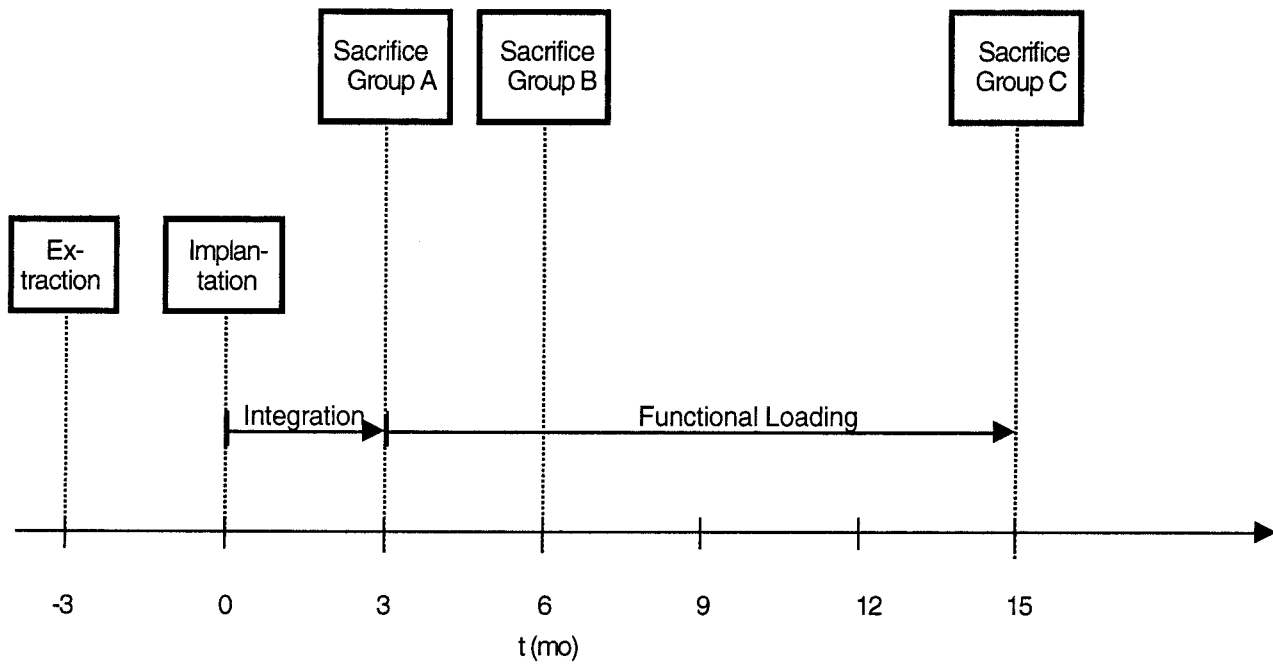


Fig. 2. Study design outlining three different groups of animals, A, B and C. Only animals in group B and C had restorations placed. Animals in group C had implants in place for 15 months with restorations for 12 months.

ginning, approximately 2 years of age and had a body weight of about 30–35 kg. None of the dogs had heartworms and all of them were quarantined prior to the start of the study.

All implants had a cylindrical hollow-screw design and were made from cold-worked, grade-IV commercially pure titanium (Institut Straumann AG, Waldenburg/BL, Switzerland) exhibiting an outer diameter of 4.1 mm and a total length of 9 mm. The suprabony, relatively smooth portion of each implant was machined (Fig. 1). The infrabony portion, 6 mm in length, had either a titanium plasma-sprayed (TPS) or a sandblasted large-grit acid-etched (SLA) surface. The results based on the two different surfaces used in this study have been reported elsewhere (Cochran et al. 1998).

Surgical treatment

All surgical procedures and histological preparation have been previously described and are explained in brief (Cochran et al. 1997). Tooth extractions were carried out in an operating room and performed under general anesthesia. Sulcular incisions were made, and all 4 premolars (P_1 – P_4) as well as the first molar (M_1) were gently removed. Prior to extraction, P_2 – M_1 were sectioned to avoid tooth fracture. Wound margins were adapted with interrupted sutures. The dogs were briefly anesthetized for suture removal after a period of 7–10 days.

After a healing period of 3 months, non-submerged titanium implants were placed under the same conditions as the tooth extractions (Fig. 2). A crestal incision was made maximizing keratinized gingiva on each side of the incision. Full-thickness flaps were gently reflected on the lingual and buccal aspect. The edentulous osseous ridge was carefully flattened using an acrylic burr and copious irrigation with chilled sterile physiological saline. Measurements were made using a Boley gauge to distribute 6 test implants on each side of the lower jaw. The implant recipient site was prepared with torque reduction rotary instruments at 500 r.p.m. using again chilled saline. Three of each kind of test implants were placed per side in an alternating manner according to a randomized starting selection. Three out of the possible 72 implants could not be placed due to anatomical limitations resulting in a total of 69 inserted implants. Horizontal mattress and interrupted sutures were placed. After 7–10 days, sutures were removed as described earlier. Mechanical and chemical plaque control was carried out 3 times per week for the duration of the study using 0.2% chlorhexidine gel (PlakOut[®] Gel, Hawe-Neos AG, Bioggio/TI, Switzerland) in combination with a soft toothbrush and a soft sponge.

Prosthetic reconstruction

Four out of the 6 dogs formed the loaded implant groups, B and C (Fig. 2). Individual impressions

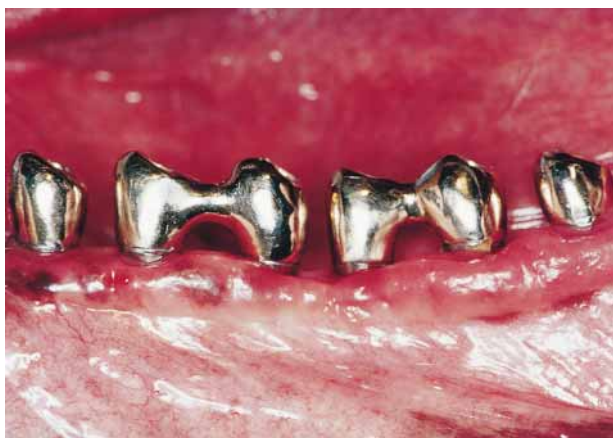

Fig. 3. This photograph demonstrates multi- and single-unit gold crowns (screw-retained) *in situ* in the P₁-M₁ area of the canine mandible.

were taken in these dogs 2 months after implant placement, and consequently, screw-retained gold crowns were fabricated (Fig. 3). To imitate the natural dentition of the dogs as closely as possible, the P₁ area had single crowns placed, whereas in the P₂-M₁ area, connected crowns on 2 implants were made. In some cases the connected crowns were sectioned as a passive fit was not achieved on both implants. Octa[®] abutments (ITI[®] Dental Implant System, Institut Straumann AG, Waldenburg/BL, Switzerland) were placed in the implants and precise impressions were taken using repropositional transfer copings. Implant analogs were placed in the impressions and models made for fabrication of the restorations. Highly precise gold copings were incorporated into the wax-ups for the crowns and bridges. All parts used were standard components of the ITI[®] Dental Implant System (Institut Straumann AG, Waldenburg/BL, Switzerland). Restorations were inserted 3 months after implant placement (Fig. 2).

Sacrifice

Two out of 6 dogs (group A) were sacrificed after a healing period of 3 months and constituted the unloaded implant group (Fig. 2). The other 4 dogs

were sacrificed after loading, 2 of them after 3 months (group B) and 2 after 12 months of loading (group C), respectively. Mandibles were block-resected and the recovered segments with the implants were immersed in a solution of formaldehyde 4% combined with CaCl₂ 1% for histologic preparation and analysis. Each implant with surrounding tissues was prepared for histology as described by Schenk et al. (1984). Briefly, radiographs were taken after the tissue blocks had been fixed in neutralized formalin (4% with 1% CaCl). The specimens were dehydrated and embedded without prior decalcification in methylmethacrylate. Around 500 μm thick saw cuts were made with a diamond blade. From each implant 2 axially oriented sections in the bucco-lingual plane were obtained and the remaining parts of the block were glued together and cut in a transverse plane. This allowed optimal harvest of 6–8 orthograde sections through the interface. They were ground to a final thickness of about 80 μm and stained with toluidine blue, followed by basic fuchsin as a counterstain. Histometric quantification was carried out utilizing a high-resolution video camera (CCD-color video camera, Sony Corporation, Fujisawa, Japan) interfaced to a video monitor (Hyper HAD video monitor, Sony Corporation, Fujisawa, Japan). This optical system was associated with a digitizing pad and a bone morphometry software package with image capturing capabilities (Bioquant bone morphometry software, R & M, Biometrics Inc., Nashville, TN, USA). All sections were analyzed under several magnifications of light microscopy to locate anatomical reference points (Table 1, Figs 4–8).

Statistical analysis

Each of the readings for the measurements taken from the oro-facial sections were averaged so that each implant had a single value for each measurement. Implant measures were compared across the 3 treatment groups by Analysis of Variance (ANOVA). If the ANOVA was statistically significant ($P < 0.05$), then pairwise comparisons were made between groups using the Bonferroni method to

Table 1. Measurements for implants Group A, B, and C (mean±standard deviation [mm], *i*=number of implants (used for ANOVA), *n*=number of measured implant sites; SD=Sulcus Depth, JE=Junctional Epithelium, CTC=Connective Tissue Contact, BW=Biologic Width)

Variable(s)	Group A	<i>i</i>	<i>n</i>	Group B	<i>i</i>	<i>n</i>	Group C	<i>i</i>	<i>n</i>
SD	0.49±0.32	20	77	0.50±0.30	24	93	0.16±0.14	24	178
JE	1.16±0.47	20	76	1.44±0.41	24	93	1.88±0.81	24	172
CTC	1.36±0.64	21	80	1.01±0.32	24	93	1.05±0.38	24	173
BW	3.01±0.74	20	76	2.94±0.59	24	93	3.08±0.78	24	172

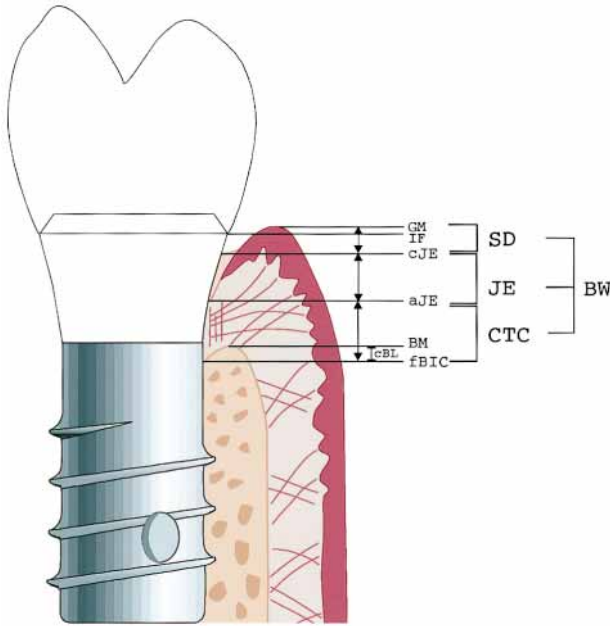


Fig. 4. Schematic of histometric measurements indicating the following distances evaluated: Distance between the gingival margin (GM) and the most coronal point of the Junctional Epithelium (cJE)=Sulcus Depth (SD). Distance between cJE and the most apical point of the Junctional Epithelium (aJE)= Junctional Epithelium (JE). Distance between aJE and the first Bone-to-Implant Contact (fBIC)=Connective Tissue Contact (CTC). SD+JE+CTC=Biologic Width (BW). Distances between the Interface (IF) and the GM, cJE, aJE, BM, and the fBIC.

identify group differences. Analysis of Variance was also done to compare the location of the implant site in the jaws. The location was ordered from most distal to most mesial. Also, Student's unpaired *t*-tests were performed to determine any differences between the two types of implants. In addition to the measurements indicated in the Histometric Analysis, the proportion of Biologic Width attributable to SD, JE, and CTC was also analyzed.

Results

Clinical observations

Postoperative healing after implant placement was uneventful in all dogs. Following 3 months of healing, all 69 implants demonstrated successful tissue integration with no mobility and no signs of peri-implant infection. No radiolucencies were apparent on radiographic examination. Forty-eight implants in groups B and C were restored with single crowns or fixed partial dentures. After loading, all implants were stable and no complications occurred in the follow-up period (up to 12 months of restoration).

Histometric analysis

The overall dimensions of the Sulcus Depth, length of Junctional Epithelium and area of Connective Tissue Contact combined (=Biologic Width) were not significantly different between the evaluation time periods (Fig. 5 and Table 1). This finding is important as Group A implants were not loaded whereas Groups B and C implants were loaded.

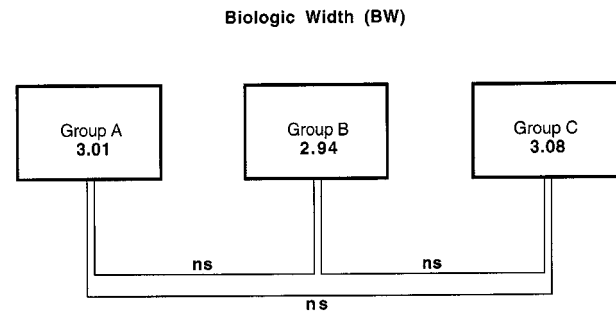


Fig. 5. Mean values [mm] for Biologic Width (BW) in Groups A, B and C. No statistically significant differences (ns) among implant groups were apparent over time ($P>0.05$).

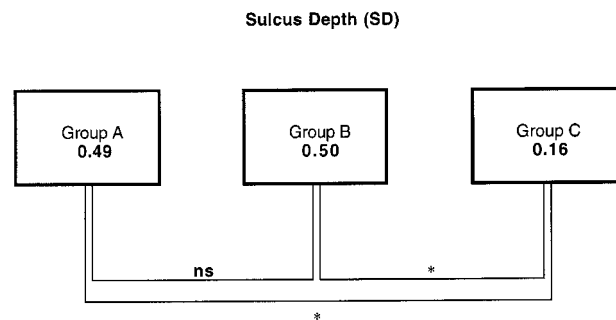


Fig. 6. Mean values [mm] for Sulcus Depth (SD) in Groups A, B and C. Significant differences (*) occurred between implants of Groups B and C as well as between A and C ($P<0.05$). No significant differences (ns) were evident when Groups A and B were compared.

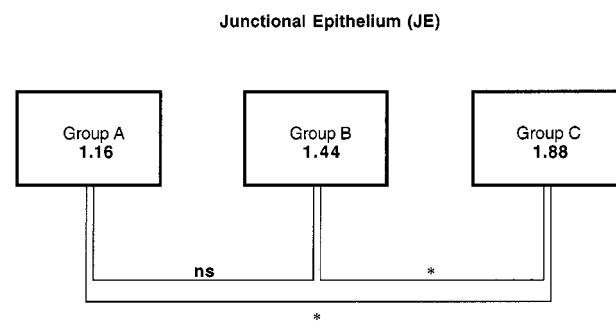


Fig. 7. Mean values [mm] for Junctional Epithelium (JE) in Groups A, B and C. Significant differences (*) were found between implants of Groups B and C as well as between A and C ($P<0.05$). No significant differences (ns) were obvious when comparing Groups A to B.

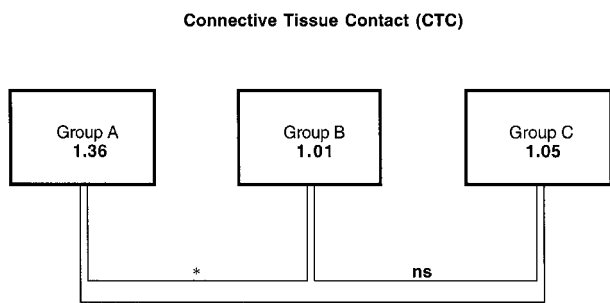


Fig. 8. Mean values [mm] for Connective Tissue Contact (CTC) in Groups A, B and C. Significant differences (*) were detected between implants of Groups A and B as well as between A and C ($P < 0.05$). No significant differences (ns) were noted comparing Groups B with C.

The mean values for the Biologic Width of Group A implants was 3.01 mm, Group B implants was 2.94 mm and Group C implants was 3.08 mm. No significant difference was noted between Group A implants compared to Group B or Group C implants, nor was there a difference between Group B and Group C implants. The dimension of Sulcus Depth however changed over the 3 healing periods (Fig. 6). Implants in Groups A and B were not significantly different with mean dimensions of 0.49 mm and 0.50 mm, respectively. In contrast, however, the Sulcus Depth around implants in Group C were significantly different from implants in both Groups A and B with a diminished mean Sulcus Depth value of 0.16 mm.

The length of the Junctional Epithelium along the implant surface reflected the changes observed for Sulcus Depth (Fig. 7). Thus, for Junctional Epithelium, no significant difference was found between implants in Groups A and B with mean values of 1.16 mm and 1.44 mm, respectively. In contrast, the dimension for the Junctional Epithelium around Group C implants was significantly increased compared to implants in Groups A and B with a mean value of 1.88 mm.

The area of Connective Tissue Contact along the implant showed a different response compared to the dimensions found for Sulcus Depth and Junctional Epithelium (Fig. 8). In the case of Connective Tissue Contact, the dimension after 3 months of non-loaded healing was 1.36 mm and was significantly different from the 6 month and 15-month healing periods (Groups B and C, respectively). The dimensions for Connective Tissue Contact were decreased for implants in groups B and C with values of 1.01 mm and 1.05 mm, respectively which were not significantly different from one another.

A comparison of the changes in the Biologic Width as determined by the linear dimensions of

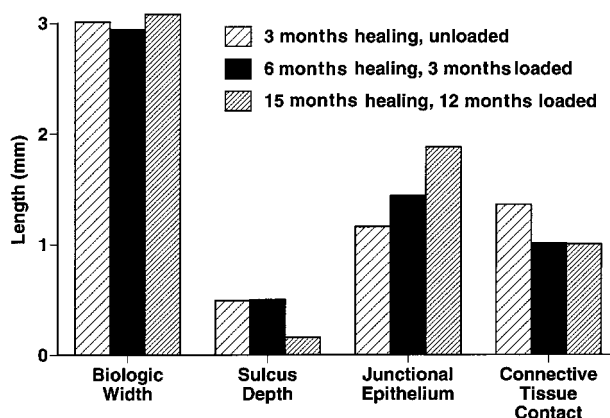


Fig. 9. Linear dimension of Biologic Width, Sulcus Depth, Junctional Epithelium and Connective Tissue Contact. Values are compared for each area over the three healing periods of 3, 6 and 15 months where implants were loaded after 3 months.

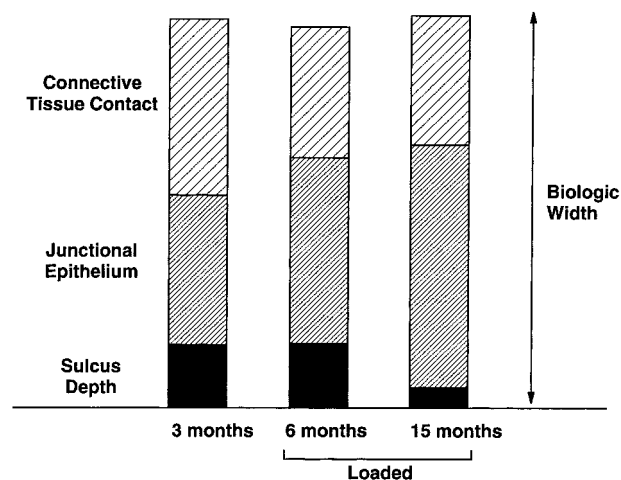


Fig. 10. Dimensional changes in Connective Tissue Contact, Junctional Epithelium and Sulcus Depth comprising the Biologic Width. The Junctional Epithelium dimension increases over time while Connective Tissue Contact and Sulcus Depth decreases.

Sulcus Depth, Junctional Epithelium and Connective Tissue Contact are shown in Fig. 9 and Fig. 10. Fig. 9 demonstrates that Sulcus Depth and Connective Tissue Contact decreases over time, but that the decrease occurs earlier in the healing process for connective tissue compared to the decrease in Sulcus Depth. Fig. 10 demonstrates that while the Biologic Width dimension stays approximately the same over the 15-month healing period, the increase in linear dimension occurs in Junctional Epithelium and compensates for the decrease in Sulcus Depth and Connective Tissue Contact.

Discussion

This study has evaluated the dimensional changes in the soft tissues around non-submerged, one-

piece titanium dental implants over a period up to 15 months and included both a non-loaded period and a loaded period. The most significant finding was that the combined dimension of soft tissues, the Biologic Width, did not change over the three evaluation periods. Additionally, significant changes did occur within the soft tissue compartments such that Sulcus Depth and Connective Tissue Contact dimensions decreased over time while the length of the Junctional Epithelium increased. The fact that the overall dimension of the Biologic Width did not change over the healing period suggests that the non-submerged, one-piece design of the implant allows for overall physiologically stable peri-implant tissues. A comparison of these dimensions to those described around teeth (Gargiulo et al. 1961; Vacek et al. 1994) further suggests that this is a physiologically formed structural unit. Evidence for the stability of this unit is provided by the fact that this overall dimension did not change in spite of three times weekly mechanical and chemical oral hygiene procedures.

The additional finding that significant differences occurred within the components of the Biologic Width at the various time points measured indicate that important dynamic factors affect the Junctional Epithelium, Connective Tissue Contact and Sulcus Depth. While these factors are not known, several possibilities exist. One such factor is loading of the implant. Due to the experimental design utilized, the effect of loading cannot be definitively addressed on soft tissue remodeling as all the implants evaluated at each time point were either not loaded or loaded. Secondly, tissue maturation may certainly influence dimensional changes including collagen crosslinking in the soft connective tissues and bony remodeling, maturation for the hard connective tissues. A further possibility for the soft tissue changes could be related to the occlusal forces placed on the implants over time. Future work will need to be performed to investigate such possibilities.

Sicher (1959), in describing the soft tissue structure around teeth, indicated that the connective tissue attachment was the most stable component of the soft tissue unit while the Junctional Epithelium was more variable in its dimension. The data in the present study suggests that this finding may be applicable to the soft tissues around non-submerged, one-piece titanium implants as well. The length of the Connective Tissue Contact in this study changed 0.3 mm while the length of the Junctional Epithelium changed 0.72 mm (a 240% greater change). These changes are also consistent with the dimensions of the soft tissues reported around similar implants placed in a human study

(Buser et al. 1990). In this human study, 70 partially edentulous patients were treated with 100 non-submerged ITI® Dental Implants, restored with fixed partial dentures and evaluated after 12 months. With these implants, the implant margin was placed 3 mm coronal to the alveolar crest. In these relatively healthy tissues (mean plaque index of 0.16 and mean sulcus bleeding index of 0.26) the mean pocket depth was 2.74 mm with a mean attachment level (from the implant margin) of 2.62 mm. The attachment level calculated from the coronal aspect of the implant margin was 3.79 mm to bone indicating an approximately 1.17 mm length of connective tissue attachment. Similar levels of attachment were found in another study of 11 humans with the same type of implant where the range at 4 and 12 months was 2.78 to 3.38 mm (Hämmerle et al. 1996).

These findings are consistent with previous investigations of soft tissues around implants. Weber et al. (1996), comparing non-submerged and submerged implants in beagle dogs, found significant differences between implant types. Epithelium had a mean length of 1.18 mm for non-submerged implants and a 1.71 mm length around submerged implants. In every case where the implant was initially submerged, the epithelium was found apical to the interface (microgap) between the implant and the transgingival abutment. The length of the connective tissue attachment was larger (1.35 mm) in the non-submerged group compared to the submerged group (0.79 mm). Attachment level for non-submerged implants was located more coronally at 1.60 mm compared to 2.14 mm for submerged implants.

In studies comparing the soft tissues around teeth and implants where an implant and an abutment were connected in beagle dogs (but not restored or the abutment loosened), the apical extent of the Junctional Epithelium was 2.14 mm and the length of the Connective Tissue Contact 1.66 mm (Berglundh et al. 1991; Berglundh et al. 1992). The distance from the gingival margin to the bone crest around those implants was 3.80 mm with this dimension and the length of Connective Tissue Contact being significantly different from the same dimensions around teeth. The authors concluded that "... Junctional Epithelium terminated about 1–1.5 mm coronal to the alveolar bone crest...". This dimension combined with the expectation of marginal bone loss after a year of loading to be 1–1.5 mm (Albrektsson & Zarb 1986) suggests that the epithelium extends past the implant/abutment interface (microgap) as found in the Weber et al. (1996) study noted earlier. None of these studies described the soft tissue dimensional changes over time.

This finding of the epithelium apical to the implant/abutment interface around submerged implants was also confirmed in a study of beagle dogs (Abrahamsson et al. 1997). This more clinically relevant finding, where the abutment was loosened, contradicted earlier findings by this research team where an abutment was placed on submerged implants and never loosened (Abrahamsson et al. 1996). In this latter more experimental model, the conclusion suggested that one-piece non-submerged and two-piece submerged implant systems had similar soft tissue healing. The findings in the study, where abutments were loosened, confirmed the finding by Hermann et al. (1997), which found significant differences in crestal bone levels between one-piece and two-piece implant/abutment systems. Interestingly, in the Hermann et al. (1997) study, the presence of an implant/abutment interface (microgap) correlated with crestal bone resorption and it did not make a difference if the two-piece system was placed with a non-submerged or submerged technique. Thus, the presence of an interface on two-part implant/abutment systems appears to correlate with crestal bone loss. This does not occur with a one-piece, non-submerged technique (Hermann et al. 1997; Cochran et al. 1997).

The results of the present study suggest that dental implants can have similar soft tissue dimensions as teeth. Certain criteria, however, appear to be necessary in order to achieve this result. These criteria can be ascertained by noting similarities between teeth and implants. With natural teeth, there is a structure intended for periodontal ligament and bony integration and a separate structure for epithelial attachment. Similarly on the implants used in this study, there was a rough surface – either sandblasted and acid-etched (SLA) or titanium plasma-sprayed (TPS) – intended to promote osseous tissue integration and a coronal area of machined titanium (Fig. 1) to discourage bone apposition and encourage epithelial and connective tissue attachment/contact. Both natural teeth and the implants used in this study are one-piece structures meaning that no interface (microgap) exists to separate the coronal structure from the more apical one. Lastly, both structures resulted in a Biologic Width of similar dimensions suggesting that the physiologic reaction to a natural tooth or a non-submerged, one-piece implant is to form an overall dimensionally stable, soft tissue structural unit known as the dentogingival unit (Sicher 1959) or implantogingival unit (Cochran et al. 1997), respectively. The present results confirm the overall stability of the implantogingival unit (referred to as “perimucosal” tissues by the First European Workshop on Periodontology, Albrektsson and Is-

idor, 1994) over time with a 15-month healing period and a 12-month loading period. However, significant changes did occur within the overall dimension over time and with loading. Thus, natural teeth and non-submerged, one-piece implants share a physiologically formed and stable overall soft tissue structure over time.

Conclusion

Overall, the findings from the present investigation reveal that while changes occur in the dimensions of the Sulcus Depth, Junctional Epithelium and Connective Tissue Contact, the overall dimension was not altered whether unloaded or loaded for 1 year around non-submerged, one-piece titanium dental implants. Furthermore, these results were similar to those same dimensions around natural teeth and suggest that these two structures share physiologically formed and stable soft tissue units.

Acknowledgements

The authors would like to thank Sonja A. Bustamante, H.T. (ASCP), University of Texas Health Science Center at San Antonio (UTHSCSA) for her continuous support throughout the study as well as Richard J. Haines, DVM, Clinical Veterinarian, and his team, Laboratory Animal Resources, UTHSCSA, for exemplary care of the animals. Nancy Place, Medical Illustrator (CMI), Graphic Services, UTHSCSA, is also gratefully acknowledged for providing excellent graphic material. In addition, the authors would like to express their gratitude to James P. Simpson, B.Sc. (Eng), Ph.D., and the Institut Straumann AG for manufacturing the test implants as well as for providing the scanning electron micrograph (SEM). John D. Schoolfield, M.S., Computing Resources at UTHSCSA, is greatly appreciated for helping with the statistical analysis. This investigation has been supported by the Institut Straumann AG and a grant from the ITI-Foundation (International Team for Oral Implantology) for the Promotion of Oral Implantology, Waldenburg/BL, Switzerland (Grant 18–92/053).

Résumé

La recherche en médecine dentaire implantaire s'est surtout occupée de l'intégration des tissus durs avec beaucoup moins de données en ce qui concerne l'intégration des tissus mous comprenant l'épithélium et le tissu conjonctif. Dans l'étude présente, la jonction implanto-gingivale d'implants en titane chargés et non-chargés non-enfouis a été analysée histométriquement dans la mandibule de chiens. Chez six chiens fox-terriers, soixante-neuf implants ont été placés. Les chiens du groupe des implants non-chargés ont été tués trois mois après le placement des implants. Les implants chargés étaient restaurés avec ces couronnes en or et ces chiens ont été tués après trois mois et douze mois de charge. Des coupes histologiques non-décalcifiées ont été analysées histométriquement mesurant les dimensions de la profondeur du sillon (SD), l'épithélium de jonction (JE) et le contact de tissu conjonctif (CTC). L'évaluation histométrique a révélé des variations significatives dans ces compartiments tissulaires avec le temps ($P < 0.05$). SD avait une moyenne de 0.49 mm et 0.50 mm après respectivement trois et six mois de guérison mais était après quinze mois de 0.16 mm, ce qui est statistiquement différent. De même JE après trois et six mois

de guérison était respectivement de 1.16 mm et 1.44 mm et ces valeurs étaient significativement différentes des mesures prises après quinze mois: 1.88 mm. A trois mois, CTC était de 1.36 mm et après six et quinze mois respectivement de 1.01 mm et 1.05 mm. Il est intéressant que la somme de SD, JE et CTC formant l'équilibre biologique de l'attache ne changeait pas durant la période d'observation ($P>0.05$). Ces données indiquent que cet espace biologique est formé physiologiquement et est un équilibre stable des structures dans le cas d'implants en titane en une pièce et non-enfous, avec ou sans charges. Des variations dynamiques sont cependant apparues avec la dimension de cet espace biologique général. L'utilisation d'implants en une pièce non-enfous permet la stabilité générale des tissus mous paroiimplantaires sous des conditions de charges allant jusqu'à douze mois.

Zusammenfassung

Die Forschung in der zahnärztlichen Implantologie hat sich meist auf die Integration in den Hartgeweben konzentriert. Ueber die Integration in den Weichgeweben, welche vor allem im Epithel und Bindegewebe stattfindet, sind nur wenige Daten vorhanden. In der vorliegenden Studie wurde die Berührungsfäche zwischen Implantat und gingivalen Geweben bei unbelasteten und belasteten transmukosal einheilenden Implantaten im einem Tierexperiment an Hunden histometrisch analysiert. Bei 6 Hunden wurden 69 Implantate eingesetzt. Die Hunde der Gruppe mit den unbelasteten Implantaten wurden 3 Monate nach dem Einsetzen der Implantate geopfert. Die belasteten Implantate wurden mit Goldkronen rekonstruiert. Die Hunde mit belasteten Implantaten wurden nach 3 und 12 Monaten Belastungszeit geopfert. Die nichtentkalkten histologischen Präparate wurden histometrisch analysiert. Gemessen wurden die Ausdehnungen der Sulkustiefe (SD), des Saumepithels (JE) und des Bindegewebskontakts (CTC). Die histologische Auswertung ergab, dass signifikante Veränderungen in der Gewebezusammensetzung (SD; JE; CTC) über die Zeit auftraten ($P<0.05$). Die Sulkustiefe zeigte einen Mittelwert von 0.49 mm und 0.50 mm nach 3 und 6 Monaten Einheilzeit. Nach 15 Monaten betrug die Sulkustiefe 0.16 mm. Der Unterschied war statistisch signifikant. Die Länge des Saumepithels betrug nach 3 und 6 Monaten 1.16 mm und bzw. 1.44 mm. Diese Werte differierten statistisch signifikant von den Messwerten, welche nach 15 Monaten aufgenommen wurden (1.88 mm). Die Region des Bindegewebskontakts zeigte ein anderes Veränderungsmuster. Nach einer Heilungszeit von drei Monaten betrug der Bindegewebskontakt 1.36 mm, während er nach 6 und 15 Monaten 1.01 mm bzw. 1.05 mm betrug. Die Unterschiede zwischen 3 und 6 bzw. 15 Monaten waren statistisch signifikant. Interessanterweise veränderte sich die Summe von SD, JE und CTC, welche die biologische Breite darstellt, während der Beobachtungsperiode nicht ($P<0.05$). Diese Daten zeigen, dass es sich bei der biologischen Breite bei transmukosal einheilenden einteiligen Titanimplantaten, welche histologisch bei belasteten und unbelasteten Implantaten ermittelt wurde, um eine physiologischerweise gebildete und über die Zeit stabile Struktur handelt. Jedoch traten dynamische Veränderungen innerhalb der einzelnen Bestandteile der biologischen Breite auf. Während der Belastungszeit von bis zu 12 Monaten konnte gezeigt werden, dass einteilige transmukosal einheilende Implantate die Bildung von alles in allem stabilen peri-implantären Weichgeweben erlauben.

Resumen

La investigación en dentistería de implantes de han enfocado principalmente sobre la integración en el tejido duro con muchos menores datos disponibles de la integración del tejido blando que incluye el epitelio y el tejido conectivo. En el presen-

te estudio se ha analizado histométricamente en la mandíbula canina la unión implantogingival de implantes de titanio no sumergidos no cargados y cargados. Se colocaron 69 implantes en 6 foxhounds. Los perros en el grupo de no carga se sacrificaron a los 3 meses tras la colocación de los implantes. Los implantes con carga se restauraron con coronas de oro y estos perros se sacrificaron después de 3 meses y 12 meses de carga. Se analizaron histométricamente secciones histológicas no descalcificadas midiendo las dimensiones de la profundidad del sulcus (SD), el epitelio de unión (JE), y el contacto de tejido conectivo (CTC). La evaluación histométrica reveló que ocurrieron a lo largo del tiempo cambios significativos ($P<0.05$) dentro de los compartimentos tisulares (SD, JE, CTC). La profundidad del sulcus tuvo una media de 0.49 mm y 0.50 mm después de 3 meses y 6 meses de cicatrización, pero tras 15 meses fue de 0.16 mm lo cual fue significativamente diferente. Similarmente, la longitud del epitelio de unión tras 3 meses y 6 meses de cicatrización fue de 1.16 mm y 1.44 mm respectivamente, y estos valores fueron significativamente diferentes de las mediciones tomadas tras 15 meses (1.88 mm). El área de contacto de tejido conectivo mostró un patrón diferente de cambio en el que después de tres meses de cicatrización (1.36 mm) fue significativamente diferente del mismo área seis meses y 15 meses los cuales fueron de 1.01 mm y 1.05 mm respectivamente. Interesantemente, la suma de SD, JD y CTC, que forman la anchura biológica no cambió a lo largo del periodo de observación ($P>0.05$). Estos datos indican que la anchura biológica es una estructura formada fisiológicamente y estable a lo largo del tiempo en el caso de implantes de titanio de una pieza no sumergidos evaluados histométricamente bajo condiciones de no carga y de carga. Occurrieron cambios mecánicos, sin embargo, dentro de la dimensión total de anchura biológica. De este modo, el uso de implantes de una pieza no sumergidos permiten unos tejidos blandos periimplantarios totales estables evaluados bajo condiciones de carga hasta 12 meses.

要旨

インプラント歯科における研究は、主に硬組織の統合に焦点があてられており、上皮と結合織に関わる軟組織の統合については、わずかのデータしかない。本研究は、犬の下顎に非埋入型のインプラントを入れ、荷重及び非荷重条件下で、インプラント歯肉境界の組織形態的分析を行った。フォックスハウンド犬6匹に、69本のインプラントを植立した。荷重インプラントはゴールド・クラウンで修復し、これらの犬は荷重3ヶ月と12ヶ月後に屠殺した。非脱灰組織切片の組織形態学的な分析を行い、歯肉溝の深さ(SD)と接合上皮(JE)の寸法、及び結合織の接触面積(CTC)を測定した。組織形態学的な評価は、経時的に軟組織コンパートメント(SD、JE、CTC)に有意の変化が生じたことを示した($P<0.05$)。歯肉溝の深さは治癒3ヶ月後及び6ヶ月後には各々平均0.49mmと0.50mmであったが、15ヶ月後には0.16mmとなり、有意差となった。同様に接合上皮の長さは治癒3ヶ月、6ヶ月後には各々1.16mmと1.44mmであったが、15ヶ月後の値は有意差を示した(1.88mm)。結合織の接触面積は異なる変化のパターン

を示し、治癒3ヶ月後の値(1.36 mm)が、6ヶ月後(1.01 mm)及び15ヶ月後(1.05 mm)とは有意に異なっていた。興味深いことに、生物学的幅径をなす、SD、JE、CTCの和は観察期間中変化しなかった($P > 0.05$)。これらのデータから、非埋入型のチタン製ワンピース・インプラントは非荷重及び荷重条件下での組織形態学的な評価において、生物学的幅径は生理的に形成され、経時的に安定した構造となることを示唆している。しかし生物学的幅径とされる寸法全体の内訳には動態的な変化が生じた。従って12ヶ月までの荷重条件下の評価においては、非埋入型ワンピース・インプラントの使用は、安定したインプラント周囲の軟組織の達成を可能とするものである。

References

- Abrahamsson, I., Berglundh, T., Wennström, J. & Lindhe, J. (1996) The peri-implant hard and soft tissues at different implant systems. A comparative study in the dog. *Clinical Oral Implants Research* 7: 212–219.
- Abrahamsson, I., Berglundh, T. & Lindhe, J. (1997) The mucosal barrier following abutment dis/reconnection. An experimental study in dogs. *Journal of Clinical Periodontology* 24: 568–572.
- Adell, R., Lekholm, U., Rockler, B. & Brånemark, P.I. (1981) A 15-year study of osseointegrated implants in the treatment of the edentulous jaw. *International Journal of Oral Surgery* 10: 387–416.
- Adell, R., Eriksson, B., Lekholm, U., Brånemark, P.I. & Jemt, T. (1990) A long-term follow-up study of osseointegrated implants in the treatment of totally edentulous jaws. *International Journal of Oral and Maxillofacial Implants* 5: 347–359.
- Albrektsson, T., Zarb, G., Worthington, P. & Eriksson, A.R. (1986) The long-term efficacy of currently used dental implants: A review and proposed criteria of success. *International Journal of Oral and Maxillofacial Implants* 1: 11–25.
- Albrektsson, T. & Isidor, F. (1994) Consensus report of session IV. In: Lang, N.P. & Karring, T., eds. *Proceedings of the 1st European Workshop on Periodontology*, p. 365, London, Berlin, Chicago, São Paulo, Tokyo, Moscow, Prague & Warsaw: Quintessence Publishing Co., Ltd.
- Babbush, C.A., Kent, J.N. & Misiek, D.L. (1986) Titanium plasma-sprayed (TPS) screw implants for the reconstruction of the edentulous mandible. *Journal of Oral and Maxillofacial Surgery* 44: 274–282.
- Becker, W., Becker, B.E., Israelson, H., Lucchini, J.P., Handelsman, M., Ammons, W., Rosenberg, E., Rose, L., Tucker, L.M. & Lekholm, U. (1997) One-step surgical placement of Brånemark implants: A prospective multicenter clinical study. *International Journal of Oral and Maxillofacial Implants* 12: 454–462.
- Behneke, A., Behneke, N. & Wagner, W. (1992) Klinische Ergebnisse mit transgingival inserierten enossalen Implantaten (Bonefit-System). *Zeitschrift für Zahnärztliche Implantologie* 8: 97–102.
- Berglundh, T., Lindhe, J., Ericsson, I., Marinello, C.P., Liljenberg, B. & Thomsen, P. (1991) The soft tissue barrier at implants and teeth. *Clinical Oral Implants Research* 2: 81–90.
- Berglundh, T., Lindhe, J., Marinello, C., Ericsson, I. & Liljenberg, B. (1992) Soft tissue reaction to *de novo* plaque formation on implants and teeth. An experimental study in the dog. *Clinical Oral Implants Research* 3: 1–8.
- Bernard, J.-P., Belser, U.C., Martinet, J.-P. & Borgis, S.A. (1995) Osseointegration of Brånemark fixtures using a single-step operating technique. A preliminary prospective one-year study in the edentulous mandible. *Clinical Oral Implants Research* 6: 122–129.
- Brånemark, P.I., Hansson, B.O., Adell, R., Breine, U., Lindström, J., Hallén, O. & Öhman, A. (1977) Osseointegrated implants in the treatment of the edentulous jaw. Experience from a 10-year period. *Scandinavian Journal of Plastic and Reconstructive Surgery* 11(suppl):16: 1–132.
- Buser, D., Stich, H., Krekeler, G. & Schroeder, A. (1989) Faserstrukturen der peri-implantären Mukosa bei Titanimplantaten. Eine tierexperimentelle Studie am Beagle-Hund. *Zeitschrift für Zahnärztliche Implantologie* 5: 15–23.
- Buser, D., Weber, H.P. & Lang, N.P. (1990) Tissue integration of non-submerged implants. 1-year results of a prospective study with 100 ITI hollow-cylinder and hollow-screw implants. *Clinical Oral Implants Research* 1: 33–40.
- Buser, D., Weber, H.P., Brägger, U. & Balsiger, C. (1991) Tissue integration of one-stage ITI implants: 3-year results of a longitudinal study with hollow-cylinder and hollow-screw implants. *International Journal of Oral and Maxillofacial Implants* 6: 405–412.
- Buser, D., Weber, H.P., Donath, K., Fiorellini, J.P., Paquette, D.W. & Williams, R.C. (1992) Soft tissue reactions to non-submerged unloaded titanium implants in beagle dogs. *Journal of Periodontology* 63: 226–236.
- Buser, D., Mericske-Stern, R., Bernard, J.P., Behneke, A., Behneke, N., Hirt, H.P., Belser, U.C. & Lang, N.P. (1997) Long-term evaluation of non-submerged ITI implants. Part I: 8-year life table analysis of a prospective multi-center study with 2359 implants. *Clinical Oral Implants Research* 8: 161–172.
- Buser, D., Mericske-Stern, R., Dula, K. & Lang, N.P. (1999) Clinical experience with one-stage, non-submerged dental implants. *Advances in Dental Research*, in press.
- Cochran, D.L., Hermann, J.S., Schenk, R.K., Higginbottom, F.L. & Buser, D. (1997) Biologic Width around titanium implants. A histometric analysis of the implanto-gingival junction around unloaded and loaded nonsubmerged implants in the canine mandible. *Journal of Periodontology* 68: 186–198.
- Cochran, D.L., Schenk, R.K., Lussi, A., Higginbottom, F.L. & Buser, D. (1998) Bone response to unloaded and loaded titanium implants with a sandblasted and acid-etched surface. A histometric study in the canine mandible. *Journal of Biomedical Materials Research* 40: 1–11.
- Collaert, B. & De Bruyn, H. (1998) Comparison of Brånemark fixture integration and short-term survival using one-stage or two-stage surgery in completely and partially edentulous mandibles. *Clinical Oral Implants Research* 9: 131–135.
- Cox, J.F. & Zarb, G.A. (1987) The longitudinal clinical efficacy of osseointegrated dental implants: A 3-year report. *International Journal of Oral and Maxillofacial Implants* 2: 91–100.
- Ericsson, I., Randow, K., Glantz, P.-O., Lindhe, J. & Nilner, K. (1994) Clinical and radiographical features of submerged and non-submerged titanium implants. *Clinical Oral Implants Research* 5: 185–189.
- Ericsson, I., Nilner, K., Klinge, B. & Glantz, P.-O. (1996) Radiographical and histological characteristics of submerged and non-submerged titanium implants. An experimental study in the labrador dog. *Clinical Oral Implants Research* 7: 20–26.
- Gargiulo, A.W., Wentz, F.M. & Orban, B. (1961) Dimensions and relations of the dentogingival junction in humans. *Journal of Periodontology* 32: 261–267.

- Gotfredsen, K., Rostrup, E., Hjørting-Hansen, E., Stoltze, K. & Butz-Jørgensen, E. (1991) Histological and histomorphometrical evaluation of tissue reactions adjacent to endosteal implants in monkeys. *Clinical Oral Implants Research* **2**: 30–37.
- Hämmerle, C.H.F., Brägger, U., Bürgin, W. & Lang, N.P. (1996) The effect of sub-crestal placement of the polished surface of ITI implants on marginal soft and hard tissues. *Clinical Oral Implants Research* **7**: 111–119.
- Henry, P.J., Laney, W.R., Jemt, T., Harris, D., Krogh, P.H.J., Polizzi, G., Zarb, G.A. & Herrmann, I. (1996) Osseointegrated implants for single-tooth replacement: A prospective 5-year multicenter study. *International Journal of Oral and Maxillofacial Implants* **11**: 443–449.
- Hermann, J.S., Cochran, D.L., Nummikoski, P.V. & Buser, D. (1997) Crestal bone changes around titanium implants. A radiographic evaluation of unloaded non-submerged and submerged implants in the canine mandible. *Journal of Periodontology* **68**: 1117–1130.
- Jansen, V.K., Conrads, G. & Richter, E.-J. (1997) Microbial leakage and marginal fit of the implant–abutment interface. *International Journal of Oral and Maxillofacial Implants* **12**: 527–540.
- Jemt, T. & Lekholm, U. (1995) Implant treatment in edentulous maxillae: A 5-year follow-up report on patients with different degrees of jaw resorption. *International Journal of Oral and Maxillofacial Implants* **10**: 303–311.
- Listgarten, M.A., Buser, D., Steinemann, S.G., Donath, K., Lang, N.P. & Weber, H.P. (1992) Light and transmission electron microscopy of the intact interfaces between non-submerged titanium-coated epoxy resin implants and bone or gingiva. *Journal of Dental Research* **71**(2): 364–371.
- Mericske-Stern, R., Steinlin Schaffner, T., Marti, P. & Geering, A.H. (1994) Peri-implant mucosal aspects of ITI implants supporting overdentures. A five-year longitudinal study. *Clinical Oral Implants Research* **5**: 9–18.
- Persson, L.G., Lekholm, U., Leonhardt, Å., Dahlén, G. & Lindhe, J. (1996) Bacterial colonization on internal surfaces of Brånemark system® implant components. *Clinical Oral Implants Research* **7**: 90–95.
- Piattelli, A., Scarano, A., Piattelli, M., Bertolai, R. & Panzoni, E. (1997) Histologic aspects of the bone and soft tissues surrounding three titanium non-submerged plasma-sprayed implants retrieved at autopsy: A case report. *Journal of Periodontology* **68**: 694–700.
- Quirynen, M. & van Steenberghe, D. (1993) Bacterial colonization of the internal part of two-stage implants. An *in vivo* study. *Clinical Oral Implants Research* **4**: 158–161.
- Romanos, G.E., Schröter-Kermani, C., Weingart, D. & Strub, J.R. (1995) Healthy human periodontal versus peri-implant gingival tissues: An immunohistochemical differentiation of the extracellular matrix. *International Journal of Oral and Maxillofacial Implants* **10**: 750–758.
- Schenk, R.K., Olah, A.J. & Hermann, W. (1984) Preparation of calcified tissue for light microscopy. In: Dickson, G.R., ed. *Methods of Calcified Tissue Preparation*, pp. 1–56. Amsterdam, New York: Elsevier Science Publishers B.V.
- Schmitt, A. & Zarb, G.A. (1993) The longitudinal clinical effectiveness of osseointegrated dental implants for single-tooth replacement. *International Journal of Prosthodontics* **6**: 197–202.
- Schroeder, A., Pohler, O. & Sutter, F. (1976) Gewebsreaktion auf ein Titan-Hohlzylinderimplantat mit Titan-Spritzschichtoberfläche. *Schweizerische Monatsschrift für Zahnheilkunde* **86**: 713–727.
- Schroeder, A., Stich, H., Straumann, F. & Sutter, F. (1978) Über die Anlagerung von Osteozement an einen belasteten Implantatkörper. *Schweizerische Monatsschrift für Zahnheilkunde* **88**: 1051–1058.
- Schroeder, A., van der Zypen, E., Stich, H. & Sutter, F. (1981) The reactions of bone, connective tissue, and epithelium to endosteal implants with titanium-sprayed surfaces. *Journal of Maxillofacial Surgery* **9**: 15–25.
- Sicher, H. (1959) Changing concepts of the supporting dental structures. *Oral Surgery, Oral Medicine, Oral Pathology* **12**: 31–35.
- Smith, D.E. & Zarb, G.A. (1989) Criteria for success of osseointegrated endosseous implants. *Journal of Prosthetic Dentistry* **62**: 567–572.
- ten Bruggenkate, C.M., Muller, K. & Oosterbeek, H.S. (1990) Clinical evaluation of the ITI (F-type) hollow cylinder implant. *Oral Surgery, Oral Medicine, Oral Pathology* **70**: 693–697.
- Tonetti, M.S., Straub, A.M. & Lang, N.P. (1995) Expression of the cutaneous lymphocyte antigen and the $\alpha^{IEL}\beta_7$ integrin by intraepithelial lymphocytes in healthy and diseased human gingiva. *Archives of Oral Biology* **40**: 1125–1132.
- Vacek, J.S., Gher, M.E., Assad, D.A., Richardson, A.C. & Giambarrresi, L.I. (1994) The dimensions of the human dento-gingival junction. *International Journal of Periodontics and Restorative Dentistry* **14**: 155–165.
- Weber, H.P., Buser, D., Donath, K., Fiorellini, J.P., Doppalapudi, V., Paquette, D.W. & Williams, R.C. (1996) Comparison of healed tissues adjacent to submerged and non-submerged unloaded titanium dental implants. A histomorphometric study in beagle dogs. *Clinical Oral Implants Research* **7**: 11–19.