

Lateral Ridge Augmentation and Implant Placement: An Experimental Study Evaluating Implant Osseointegration in Different Augmentation Materials in the Canine Mandible

Thomas von Arx, DDS, Dr Med Dent¹/David L. Cochran, DDS, PhD²/
Joachim S. Hermann, DDS, Dr Med Dent, FICOI³/Robert K. Schenk, MD, Prof Dr Med⁴/
Frank L. Higginbottom, DDS⁵/Daniel Buser, DDS, Prof Dr Med Dent⁶

The present study investigated the osseointegration of dental implants with a titanium plasma-sprayed surface (TPS) in regenerated and native bone in an experimental dog study. Initially, lateral bone defects were created in the alveolar ridge on both sides of the mandible. Two months later, lateral ridge augmentation was performed with (1) autogenous corticocancellous block grafts, (2) autogenous corticocancellous block grafts and e-PTFE membrane, (3) tricalcium phosphate particles and e-PTFE membrane, or (4) canine-derived demineralized freeze-dried bone allograft particles and e-PTFE membrane. After 4 months, membranes were removed, and non-submerged titanium implants were placed in regenerated bone (test implants) and in native bone (control implants). Two months later, the animals were sacrificed and non-decalcified orofacial sections were evaluated histometrically. All implants demonstrated high percentages (59% to 75%) of bone-to-implant contact, with no significant differences across the various treatment groups. The different grafting techniques did not significantly influence the location of first bone-to-implant contact and the horizontal bone width at the most coronal bone level. (INT J ORAL MAXILLOFAC IMPLANTS 2001;16:343-354)

Key words: *autogenous bone, barrier membrane, demineralized freeze-dried bone allograft, histometry, osseointegration, ridge augmentation, titanium implant, tricalcium phosphate*

Tooth restoration using implant-supported prostheses for functional and esthetic rehabilitation has become an established and widely used

treatment modality in dentistry. One of the most critical factors in treatment planning is bone volume at the future implant site. The quantity and quality of the bone supply not only influence implant osseointegration, but also affect the shape and contour of the overlying soft tissue and, hence, the esthetic outcome. In addition, prosthetic parameters such as restoration/implant axis and restoration/implant ratio are affected by the quantity and quality of bone at the implant site.

Following the evolution of root-form dental implants, a multitude of surgical techniques have evolved to enhance alveolar bone volume for implant placement. Among these techniques, guided bone regeneration (GBR) has become not only the most extensively studied technique but probably the most popular bone reconstructive procedure in implant dentistry. One major point of differentiation of GBR procedures is the scheduling of bone regeneration in relation to implant placement. In the staged approach, bony site development is performed usually 6 months prior to implant placement, whereas in the simultaneous approach, the bone regeneration

¹Assistant Professor, Department of Oral Surgery, School of Dental Medicine, University of Berne, Switzerland; and Visiting Associate Professor, Department of Periodontics, Dental School, University of Texas Health Science Center at San Antonio (UTHSCSA).

²Professor and Chair, Department of Periodontics, Dental School, UTHSCSA.

³Associate Professor and Head, Division of Periodontics, Department of Preventive Dentistry, Periodontics, and Cariology, University of Zurich Dental School, Switzerland; and Clinical Assistant Professor, Department of Periodontics, Dental School, UTHSCSA.

⁴Professor Emeritus, Department of Oral Surgery, School of Dental Medicine, University of Berne, Switzerland.

⁵Assistant Professor, Department of Oral and Maxillofacial Surgery and Pharmacology, Baylor College of Dentistry, Dallas, Texas; and Private Practice, Dallas, Texas.

⁶Professor and Chairman, Department of Oral Surgery, School of Dental Medicine, University of Berne, Switzerland.

Reprint requests: Dr Thomas von Arx, Department of Oral Surgery, School of Dental Medicine, University of Berne, Freiburgstrasse 7, CH-3010 Berne, Switzerland. Fax: +41-31-632-9884. E-mail: thomas.vonarx@zmk.unibe.ch

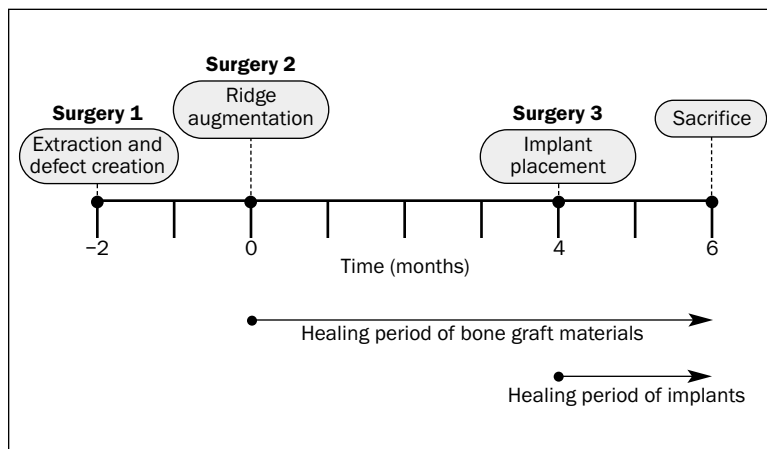


Fig 1 Time schedule of the present study.

procedure is carried out in conjunction with implant placement. Selection criteria for the appropriate surgical approach include anatomic aspects, such as the size and morphology of the bone defect. Additional and essential issues include primary implant stability and correct implant position and orientation in relation to the prosthetic restoration.¹⁻³ With respect to the staged approach, a number of clinical studies have demonstrated that implants placed subsequently into regenerated alveolar bone have excellent long-term results and maintain their peri-implant tissue status.⁴⁻⁷

These clinical results were confirmed in an experimental canine study by Buser and colleagues.⁸ In 5 dogs, acute through-and-through ridge defects were created in the mandible and immediately covered with expanded polytetrafluoroethylene (e-PTFE) membranes. No bone grafts or substitutes were applied. Following a healing period of 6 months, non-submerged implants were placed. After 3 months of implant healing, some of the implants were restored with fixed prostheses and loaded for 6 months. At the completion of the study, all implants, irrespective of loading status, demonstrated osseointegration with direct bone-to-implant contact. Peri-implant bone parameters did not differ between loaded and unloaded implants. The authors concluded that bone regenerated in membrane-protected defects responded to implant placement in the same way as non-regenerated native bone.

Other factors important in GBR are the achievement of primary soft tissue healing and the type of graft material to be used as a membrane-supporting device to avoid membrane collapse during healing.⁹ Though autogenous bone is unequivocally accepted as the gold standard for bone grafting, other filling materials have been successfully used for bone

regeneration. The main reasons to avoid the utilization of autografts are as follows: (1) the additional harvesting procedure with possible donor site morbidity, (2) a sometimes limited amount of available bone graft from intraoral sites, and (3) the higher cost and often more complex surgery for extraoral graft donor sites.

Bone regeneration with different grafting materials protected by an e-PTFE membrane was recently analyzed in an experimental study in 12 miniature pigs.¹⁰ The filler materials compared to autogenous bone included a collagen sponge, demineralized freeze-dried bone allograft (DFDBA) (from the tibia of a miniature pig), tricalcium phosphate (TCP) granules, and coral-derived hydroxyapatite granules. Autogenous bone showed the best results in the initial phase of healing (4 weeks), whereas TCP demonstrated 70% new bone formation at the completion of the study (24 weeks), compared to 54% in autografted sites.

Taking into account the findings of the above-mentioned studies,^{8,10} the authors designed the present experimental study to evaluate osseointegration of dental implants placed in bone regenerated with different grafting materials. Implants placed in augmented areas (test implants) were compared to implants placed in non-regenerated, native alveolar bone (control implants).

MATERIALS AND METHODS

Study Design and Time Schedule

Osseointegration of implants placed in regenerated bone in previously created localized bone defects was evaluated in an experimental study employing 3 dogs. Initially, all premolars and the first molar were surgically removed in the mandible (Fig 1), and 2 lat-

Table 1 Randomization of Grafting Techniques by Dog and Mandibular Bone Defect

Dog	Mesial defect in right mandible (R1)	Distal defect in right mandible (R2)	Mesial defect in left mandible (L1)	Distal defect in left mandible (L2)
Dog #2235	DFDBA + membrane	Autograft + membrane	TCP + membrane	Autograft alone
Dog #2240	Autograft alone	TCP + membrane	Autograft + membrane	DFDBA + membrane
Dog #2363	DFDBA + membrane	Autograft + membrane	TCP + membrane	Autograft alone

DFDBA = demineralized, freeze-dried bone allograft; TCP = tricalcium phosphate.

eral bone defects were created per side (see below). Two months later, lateral ridge augmentation was performed utilizing 4 different grafting treatments. Four months after augmentation surgery, dental implants were placed into regenerated bone (test implants) and into native bone (control implants). All animals were sacrificed 6 months after ridge augmentation, ie, 2 months after implant placement.

Parallel to this study, another 3 animals underwent the same surgeries except for implant placement. That part of the study evaluated reconstruction of the alveolar ridge using the same grafting techniques. Results have been published in a separate article.¹¹

Animals

Lab-bred American foxhounds were used in this study. At the beginning of the study, these animals were about 2 years old and weighed approximately 30 kg. The study was conducted according to the guidelines of the Department of Laboratory Animal Resources at the University of Texas Health Science Center at San Antonio (UTHSCSA), and the protocol was approved by the Institutional Animal Care and Use Committee.

Surgery

Pre- and postoperative medication and preparatory surgical steps were identical to those reported elsewhere.¹¹ Therefore, only a brief summary is given. All surgical procedures were performed under general anesthesia employing endotracheal intubation. In addition, local anesthesia was administered by infiltration at the respective buccal and lingual aspects of the mandibular ridge. Antibiotics were given postoperatively (benzathine penicillin, procaine penicillin G, and gentamicin).

During the first surgery, all mandibular premolars and first molars, as well as the second and third maxillary premolars, were removed. Immediately afterward, 2 lateral bone defects (14×10×8 mm) were created on each side of the mandible. Two months later, the lateral bone defects were augmented in 4 different ways,¹¹ with random assignment of each grafting condition (Table 1).

Site 1: Corticocancellous block graft and bone particles (autograft) without membrane protection

Site 2: Corticocancellous block graft and bone particles (autograft) with e-PTFE membrane

Site 3: Tricalcium phosphate granules (TCP) with e-PTFE membrane

Site 4: Canine DFDBA with e-PTFE membrane

The corticocancellous block grafts were harvested from the site of the previously extracted first molar. The autografts were immediately transplanted to their assigned defect sites and secured with a stabilization screw (Memfix, Institut Straumann AG, Waldenburg, Switzerland). Cancellous bone chips were placed on all sides around and on top of the monocortical block grafts. In each dog, 1 autografted site was subsequently covered with an e-PTFE membrane (GTAM, W.L. Gore, Flagstaff, AZ). The membrane was stabilized with 2 Memfix fixation screws at its buccal base. The third defect was grafted with DFDBA particles processed from canine tibiae (Osteotech, Shrewsbury, NJ). The graft particles measured 250 to 500 µm. The remaining defect was augmented with TCP granules, 0.7 to 1.4 mm (Ceros TCP, Robert Mathys AG, Bettlach, Switzerland), for ridge reconstruction. To prevent membrane collapse, a supporting Memfix screw was inserted into the lingual cortex in the middle of the defects were treated with DFDBA and TCP. Periosteal releasing incisions allowed for tension-free wound closure, which was accomplished with horizontal mattress and interrupted sutures. Sutures were removed 2 weeks postoperatively.

Four months after ridge augmentation, the dogs were scheduled for implant placement. A midcrestal incision with vertical release incisions was made to reflect full mucoperiosteal flaps. The e-PTFE membranes and all fixation and supporting screws were removed. Commercially available implants were placed in augmented sites when bone density and volume were adequate. A single implant was placed in the anterior augmentation site, whereas 1 or 2 implants were placed in the posterior augmentation site. Control implants were placed into native bone either between the 2 augmentation

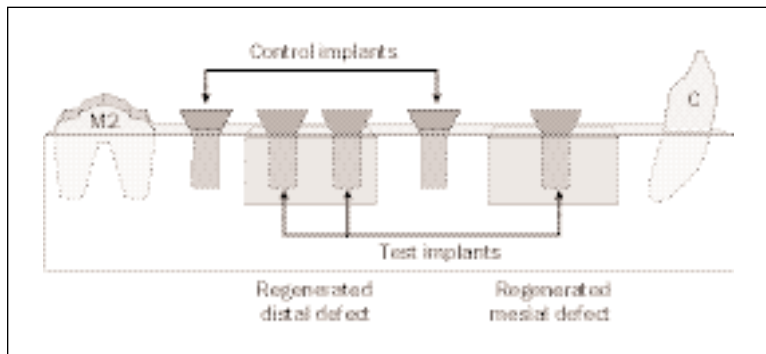


Fig 2 Schematic illustration of right mandible, showing implant placement into regenerated bone (test implants) and into native bone (control implants). C = canine; M2 = second molar.

Table 2 No. of Implants Placed per Treatment Group

Treatment	Specimens	No. of implants
Autograft alone	Test	2
Autograft + membrane	Test	5
TCP + membrane	Test	3
DFDBA + membrane	Test	3
Native bone	Control	6
Total		19

sites and/or distal to the posterior augmentation site (Fig 2). Two different types of ITI titanium plasma-sprayed dental implants (ITI Dental Implant System, Institut Straumann, Waldenburg, Switzerland) were used: 6-mm hollow-screw implants (HS-6) and 8-mm solid-screw implants (S-8), both with an outer diameter of 4.1 mm. Implants placed at anterior augmentation sites were always HS-6 implants, whereas all other sites received S-8 implants. Implant beds were prepared according to the standard ITI surgical protocol. The implants were placed in a non-submerged technique, with flaps reapproximated around the implants using multiple interrupted sutures. A total of 19 implants were placed (13 test and 6 control) (Table 2).

Oral hygiene procedures, including implant cleansing, were carried out 2 times a week using 0.2% chlorhexidine gel (Plak-Out Gel, Hawe Neos Dental, Biaggio, Switzerland). A soft diet was maintained throughout the study.

Sacrifice

All animals were sacrificed 2 months after implant placement, ie, 6 months after ridge augmentation. Euthanasia was performed with an overdose of pentobarbital sodium 0.2 mL intravenously (65 mg/kg, Euthanasia-5, Henry Schein, Port Washington,

NY). Subsequently, the mandibles were block-resected using an oscillating autopsy saw, and the recovered segments were immersed in a solution of 4% formaldehyde combined with 1% calcium chloride prior to histologic preparation.

Histologic and Histometric Analysis

The specimens were prepared for histology as described by Schenk and coworkers.¹² Briefly summarized, non-decalcified specimens were embedded in methyl methacrylate resin and stained with toluidine blue and basic fuchsin. Consecutive orofacial step sections with a thickness of approximately 80 μ m, spaced at intervals of about 1 mm, were obtained for histologic and histometric analysis. For each implant site, all sections showing the implant body were evaluated. Histometric quantification was carried out under a light microscope utilizing a high-resolution videocamera coupled to a computer monitor. A morphometry software package (Image Pro Plus, Media Cybernetics, Silver Spring, MD) with image-capturing capabilities was employed to measure the following parameters (Fig 3).

- fBIC = first bone-to-implant contact (mm) measured from the implant shoulder (at $\times 12.5$ magnification)
- HBW = horizontal bone width (mm) at level of first bone-to-implant contact (at $\times 12.5$ magnification)
- BIC = percentage of bone-to-implant contact from first bone-to-implant contact down to where the implant begins to curve at the apical end (at $\times 31.25$ magnification)

All parameters were measured on the buccal and lingual aspects of the implants. Osseointegration was defined according to Brånemark and associates¹³ as direct bone-to-implant contact without intervening soft tissues.

Statistical Analysis

The statistical analysis involved comparisons across treatment groups as well as buccal versus lingual. Histometric data were obtained for at least 3 sections taken from each implant site. The data were averaged so that each measure had a single value per implant to be used for statistical analysis. For the comparisons across treatment groups, analysis of variance was performed for each histometric parameter at the buccal and the lingual, as well as the difference between the buccal and lingual measures. When the resulting F tests were statistically significant ($P < .05$), Bonferroni-adjusted unpaired Student t tests (with $P < .05$ considered significant) were performed to identify individual treatment group differences. For each treatment group, the corresponding buccal and lingual histologic measures were compared by paired Student t tests (with $P < .05$ considered significant). Since the small sample sizes had the potential of producing Type II errors, marginally significant results ($P < .10$) involving mean differences greater than 1 mm were also reported.

RESULTS

Clinical Findings

Following ridge augmentation, 2 membrane-covered sites in the same animal showed extended membrane exposures (dog #2240, right posterior site with TCP + membrane and left posterior site with DFDBA + membrane). Three weeks after surgery 2, these exposed membranes were surgically removed. Subsequent wound healing was uneventful. The overall membrane exposure rate was 22% (2 of 9 membrane sites). In surgery 3, implants could be placed at both sites with previous membrane exposure. The number of test implants placed per grafting condition in surgery 3 varied. For instance, no implants could be placed in 2 sites because of severe resorption or loss of the bone grafting material (1 "autograft alone" site and 1 "DFDBA + membrane" site). In contrast, 2 implants instead of a single implant could be placed in 3 sites with exceptionally good bone regeneration (2 "autograft + membrane" sites and 1 "DFDBA + membrane" site). This led to diverging numbers of implants evaluated per grafting group. No implants were lost, and all implants were clinically stable at the completion of the experiment.

Histologic Observations

Experimental Implants in "Autograft Alone" Sites. Only 2 implants had been placed in autografted sites without membrane application. In 1 site, the

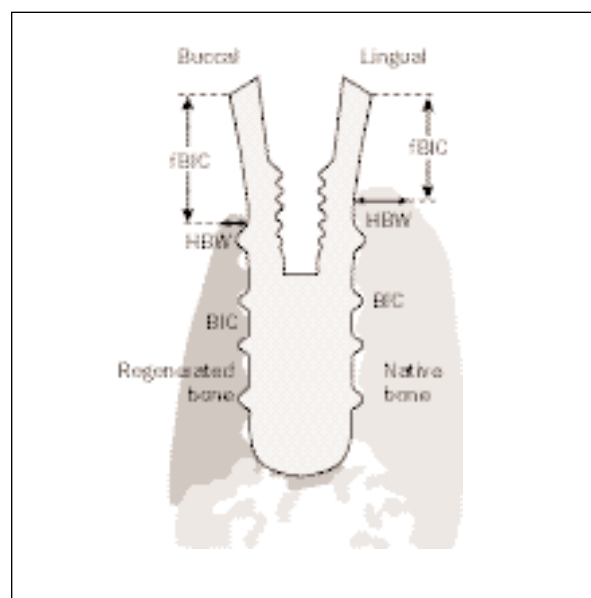


Fig 3 Schematic illustration of histometric analysis with measurements of first bone-to-implant contact (fBIC), horizontal bone width (HBW), and percentage of bone-to-implant contact (BIC) on buccal and lingual aspects.

buccal wall was critically thin but reached the level of the former alveolar crest (Fig 4a). The other site showed an inadequate crestal contour but good reconstruction of the buccal wall (Fig 4b). The grafted bone exhibited good remodeling. However, the periosteal surface showed ongoing osteoclastic resorption (Fig 4c).

Experimental Implants in "Autograft with Membrane" Sites. Five implants had been placed into sites regenerated with membrane-protected autografts. All of these sites showed a well-preserved crestal contour with adequate ridge width. All sites demonstrated good buccal bone dimensions, generally reaching the coronal TPS level of the placed implant. The outer surface of the transplanted corticocancellous block grafts usually demonstrated little surface resorption, thus re-establishing the original dimension of the buccal cortex (Figs 5a and 5b). Similarly, the cortical bulk of the block graft had undergone little remodeling, and only a limited number of new Haversian systems were present (Fig 5c). New bone formation was more extensive in the cancellous portion of the graft facing the buccal implant surface and around the block graft where the cancellous chips had been placed.

Experimental Implants in "TCP with Membrane" Sites. Three implants had been placed into regenerated sites using TCP particles with membrane coverage. Two specimens with buccal inclination of the

Figs 4a to 4c Defects treated with corticocancellous block grafts without membrane placement. Undecalcified ground sections surface-stained with toluidine blue and basic fuchsin. The buccal wall of the specimens is always oriented to the right.

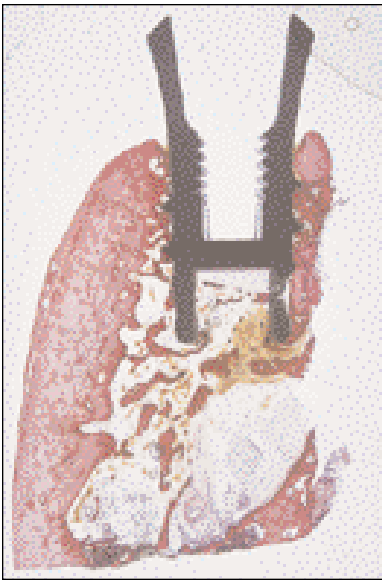

Fig 4a Implant placed just coronal to the mental foramen. The unprotected block graft underwent extensive resorption, but the bone-to-implant contact remained intact (magnification $\times 2$).

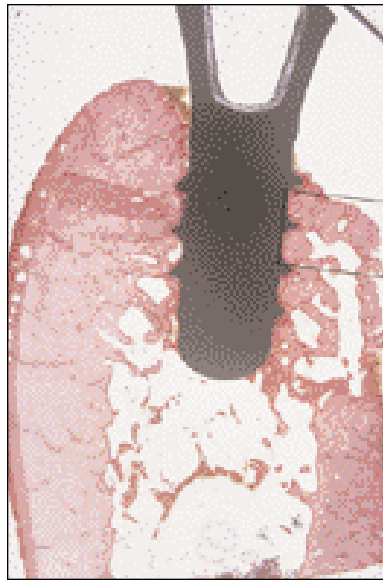

Fig 4b This specimen shows good reconstruction of the former alveolar width. Most of the corticocancellous graft is preserved, except for the buccocrestal aspect, which underwent active resorption (magnification $\times 2$).

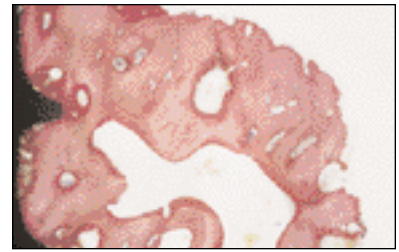


Fig 4c Coronal portion of the autogenous block graft. The implant surface is almost completely covered with newly formed bone, except for a small area with primary contact at the lower thread. The cortical graft underwent quite intense remodeling, with most remodeling units being in the formative stage. Osteoclastic resorption dominates along the full extent of the surface exposed to the periosteum (magnification $\times 10$).

Figs 5a to 5c Defects treated with corticocancellous block grafts and e-PTFE membrane placement. Undecalcified ground sections surface-stained with toluidine blue and basic fuchsin. The buccal wall of the specimens is always oriented to the right.

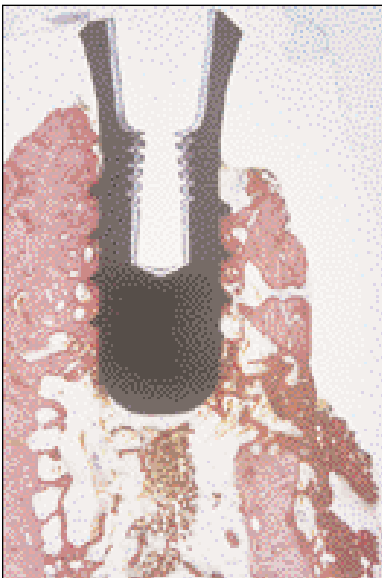

Fig 5a Worst case of the membrane-protected autograft due to the small size of the block graft. Extensive bone-to-implant contact can be seen on both implant aspects (magnification $\times 10$).

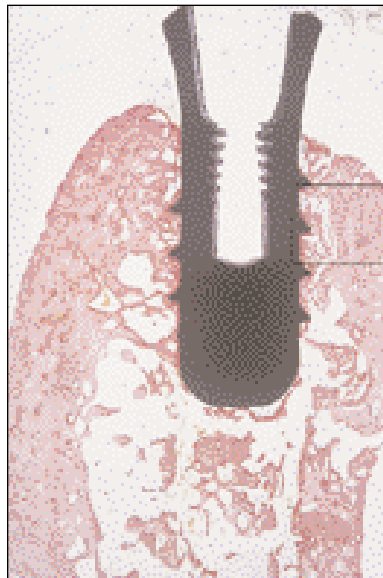

Fig 5b Best case of a membrane-protected corticocancellous autograft, demonstrating full osseointegration of the implant (magnification $\times 2$).

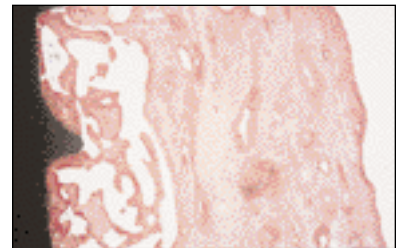


Fig 5c Bony ongrowth has led to extensive contact of this corticocancellous block graft with the implant surface. Most of the grafted compact bone is avascular and devitalized, and remodeling has just started. The smooth periosteal surface indicates that membrane protection has prevented osteoclastic resorption (magnification $\times 10$).

Figs 6a to 6c Defects treated with TCP particles with e-PTFE membrane placement. Undecalcified ground sections surface-stained with toluidine blue and basic fuchsin. The buccal wall of the specimens is always oriented to the right.

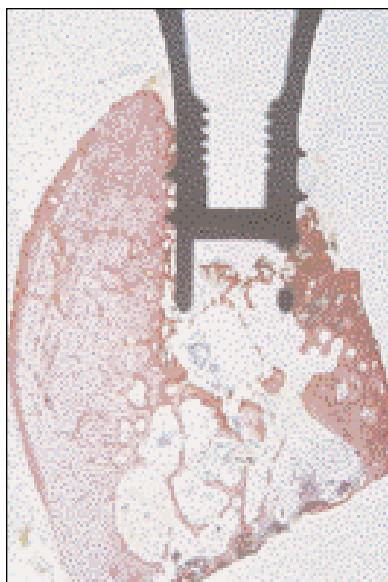

Fig 6a The marked asymmetry between the buccal and lingual bone plates is a result mainly of the angulation of the implant. The 2 coronal threads on the buccal aspect are covered by soft tissue (magnification $\times 2$).

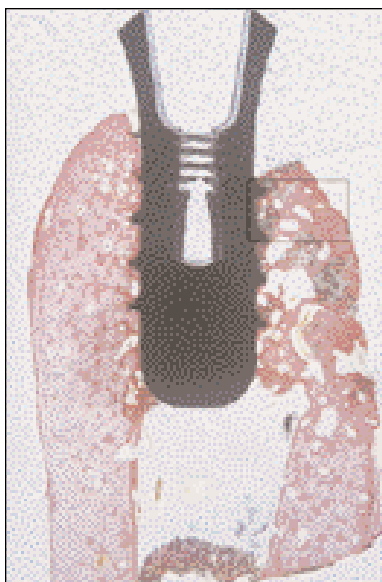


Fig 6b The fully regenerated buccal bone plate is as wide as the lingual cortex but slightly reduced in height. Full bone-to-implant contact has been achieved (magnification $\times 2$).

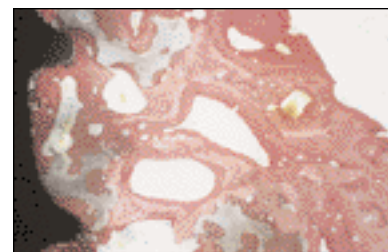


Fig 6c Grafting with TCP particles and membrane protection has reconstructed a rather solid buccal bone plate. Extensive bone-to-implant contact is seen. Remnants of TCP particles are in close proximity to the implant surface and embedded in newly formed bone. Remodeling and substitution have started. Membrane protection has promoted new bone formation and has prevented osteoclastic resorption along the periosteal surface (magnification $\times 10$).

implant axis showed less than adequate bone regeneration buccally, resulting in a critically thin buccal bone plate at the crestal level (Fig 6a). This finding was associated with reduced bone height on the buccal aspect of the implant. One site demonstrated good reconstruction of the buccal bone wall (Fig 6b). Most of the previously grafted TCP particles had been incorporated into bone that had been regenerated since augmentation in the periods before and after implant placement (Fig 6c). Substitution of the graft material was not yet complete.

Experimental Implants in "DFDBA with Membrane" Sites. Three implants had been placed into regenerated bone following osteopromotion by canine DFDBA with membrane coverage. Two sites demonstrated a very thin bony layer on the buccal implant surface (Fig 7a). However, this bone almost always reached the coronal TPS level of the implant. One site showed excellent bone regeneration, with good buccal bone width (Fig 7b). The DFDBA particles were incorporated into newly formed woven and lamellar bone (Fig 7c). However, the density of regenerated bone was low.

Control Implants in "Native Bone" Sites. Six implants had been placed into non-regenerated bone. The buccal bone height almost always reached the coronal TPS level and demonstrated adequate width

unless the implant was angulated to the buccal aspect (Fig 8a). Since the cortical bone wall had not been removed at the control sites, normally dense, compact bone was found at both the buccal and lingual implant aspects (Fig 8b). This bone showed characteristic remodeling, with newly formed osteons in the area adjacent to the implant surface (Fig 8c).

Histometric Results

The mean data per treatment group of the 3 histometrically evaluated parameters are listed in Table 3. A summary of the statistical data is given in Table 4.

Analysis of fBIC. Treatment means calculated for first bone-to-implant contact (fBIC) ranged from 3.80 to 4.70 mm (controls, 3.87 mm) for buccal aspects and from 2.67 to 3.98 mm (controls, 3.2 mm) for lingual aspects. The most coronal levels of bone were found in "DFDBA + membrane" sites. A significantly greater lingual fBIC ($P < .05$) was calculated for "autograft alone" sites compared to "DFDBA + membrane," "autograft + membrane," and control sites, but no significant difference was observed at "TCP + membrane" sites. The lingual fBIC of "TCP + membrane" was also significantly greater than that of "DFDBA + membrane" sites ($P < .05$). No statistically significant differences were found between buccal and lingual fBICs within any of the treatment

Figs 7a to 7c Defects treated with DFDBA particles and e-PTFE membrane placement. Undecalcified ground sections surface-stained with toluidine blue and basic fuchsin. The buccal wall of the specimens is always oriented to the right.

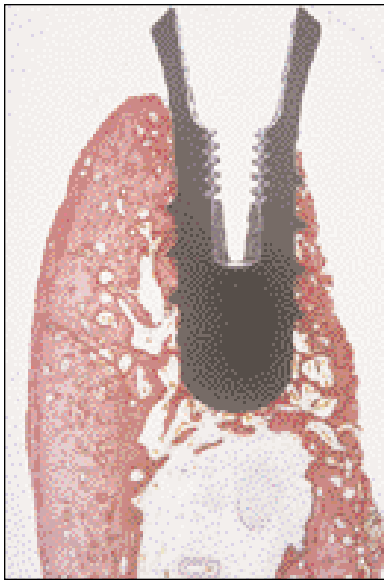

Fig 7a The buccal wall is thin but reaches the smooth/rough implant border. Extensive bone-to-implant contact is present (magnification $\times 2$).

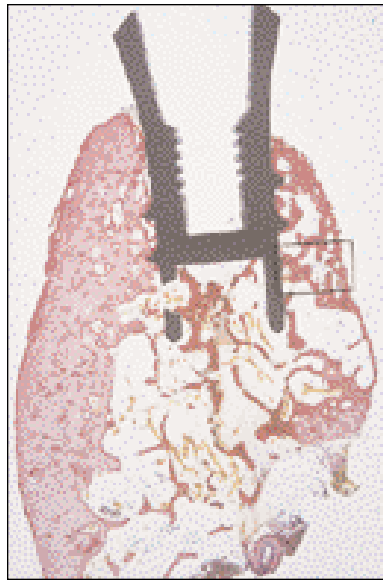

Fig 7b The buccal wall is remarkably wide. It consists mostly of cancellous bone, confined by a thin cortical layer formed underneath the membrane (magnification $\times 2$).

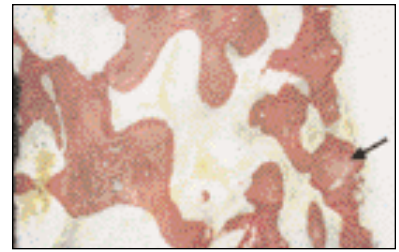


Fig 7c This case of augmentation with DFDBA particles and membrane protection provided a result comparable to the TCP graft. A somewhat higher magnification ($\times 16$) was chosen for easier identification of remnants of DFDBA particles (arrow) that, after incorporation in new bone, underwent recalcification.

Figs 8a to 8c Undecalcified ground sections from non-augmented control sites surface-stained with toluidine blue and basic fuchsin. The buccal wall of the specimens is always oriented to the right.

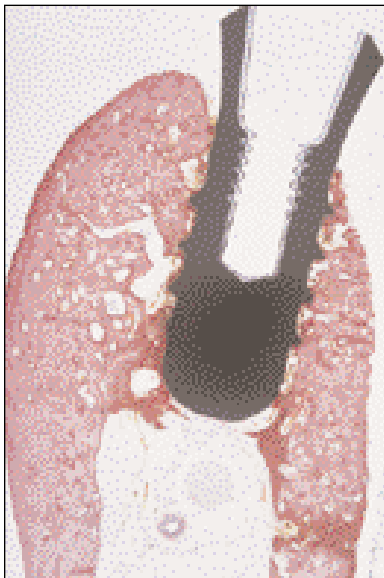


Fig 8a This control specimen illustrates the asymmetry between the lingual and buccal walls resulting from the buccally angulated implant position. Structure and bone remodeling as well as bone-to-implant contact are identical on both sides of the implant (magnification $\times 2$).

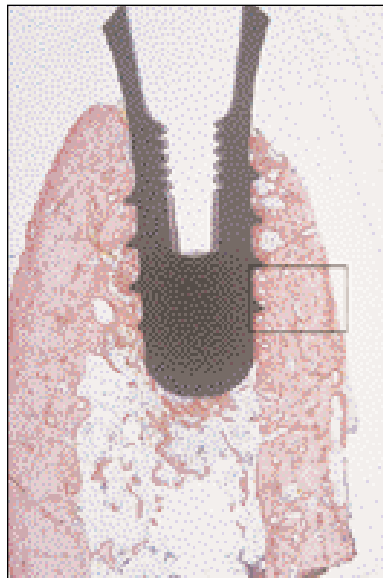


Fig 8b This control implant is in an axial position and supported by almost symmetric lingual and buccal walls, both consisting of compact bone with comparable remodeling activity (magnification $\times 2$).

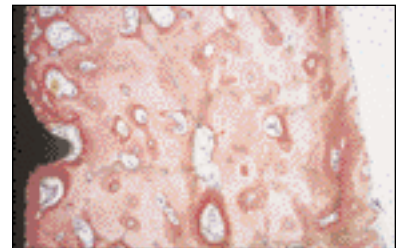


Fig 8c This part of the buccal wall underwent intense remodeling, a result of the interruption of the blood supply during implantation. Extensive secondary bone-to-implant contact ensures osseointegration. The periosteal surface has not been subjected to osteoclastic resorption (magnification $\times 12.5$).

Table 3 Data of Test and Control Sites (Mean \pm SD)

Parameter	Autograft alone	Autograft + membrane	TCP + membrane	DFDBA + membrane	Control sites
fBIC buccal (mm)	4.62 \pm 0.67	3.92 \pm 0.84	4.70 \pm 1.41	3.80 \pm 0.49	3.87 \pm 0.86
fBIC lingual (mm)	3.98 \pm 0.15	3.13 \pm 0.13	3.46 \pm 0.57	2.67 \pm 0.37	3.20 \pm 0.15
HBW buccal (mm)	0.85 \pm 0.53	1.22 \pm 0.64	1.04 \pm 0.44	0.32 \pm 0.20	1.09 \pm 0.76
HBW lingual (mm)	3.08 \pm 1.09	2.63 \pm 0.76	2.41 \pm 0.84	2.26 \pm 0.31	2.10 \pm 0.79
BIC buccal (%)	58.8 \pm 19.6	74.1 \pm 6.6	75.0 \pm 2.5	74.2 \pm 11.6	73.7 \pm 7.5
BIC lingual (%)	65.2 \pm 17.0	76.3 \pm 5.5	66.8 \pm 8.6	69.1 \pm 19.6	76.4 \pm 9.9

fBIC = first bone-to-implant contact measured from implant shoulder, which is placed 2.8 mm coronal to the alveolar crest; HBW = horizontal bone width at fBIC; BIC = bone-to-implant contact along implant surface from fBIC to bottom of implant.

Table 4 Summary of Statistically Significant Differences for Evaluated Parameters

Parameter	Buccal means compared among groups	Lingual means compared among groups	Buccal compared to lingual means within groups	Difference of buccal and lingual means among groups
fBIC, by grafting technique	$F = 0.72, P > .58$ No significant differences	Autograft alone > DFDBA/membrane, autograft/membrane, control ($P < .05$) TCP/membrane > DFDBA/membrane ($P < .05$) $F = 7.04, P < .01$	Buccal > lingual for autograft/membrane (marginal, $P = .08$)	$F = 0.38, P > .81$ No significant differences
HBW, by grafting technique	$F = 1.13, P > .38$ No significant differences	$F = 0.75, P > .57$ No significant differences	Lingual > buccal for autograft/membrane and for DFDBA/membrane ($P < .025$)	$F = 0.57, P > .68$ No significant differences
BIC, by grafting technique	$F = 1.33, P > .30$ No significant differences	$F = 0.78, P > .55$ No significant differences	No significant differences ($P > .17$)	$F = 1.38, P > .28$ No significant differences

conditions, but buccal was marginally ($P = .08$) greater than lingual for “autograft + membrane” sites.

Analysis of HBW. Treatment means calculated for the horizontal bone width (HBW) measured at the level of the first bone-to-implant contact ranged from 0.32 to 1.22 mm (controls, 1.09 mm) on buccal aspects and from 2.26 to 3.08 mm (controls, 2.1 mm) on lingual aspects. Buccally, “autograft + membrane” sites had the highest mean HBW, whereas lingually, “autograft alone” sites showed the greatest mean HBW. Generally, the mean buccal HBWs were 2 to 7 times smaller than their lingual counterparts when the lingual dimension exceeded 2 mm. However, a significantly smaller buccal HBW ($P < .025$) compared to the lingual HBW was seen for only “autograft + membrane” and for “DFDBA membrane” sites. Comparisons across the different grafting conditions and control sites revealed no statistically significant differences for mean buccal or lingual HBW measurements.

Analysis of BIC. Treatment means calculated for BIC ranged from 58.8% to 75.0% (controls, 73.7%) on the buccal implant surface and from 65.2% to 76.3% (controls, 76.4%) on the lingual implant surface. Sites treated with TCP and DFDBA had more BIC on the buccal compared to the lingual implant surface, whereas autografted sites (with or without a membrane) and control sites had higher BIC on the lingual surface. A comparison of buccal versus lingual BICs revealed no significant differences across and within the different treatment conditions.

DISCUSSION

The first experimental study evaluating an osteopromotive technique (subsequently termed *guided bone regeneration*, or *GBR*) in conjunction with root-form dental implants was published by Dahlin and coworkers.¹⁴ Thirty submerged titanium implants

with a machined surface were placed in the tibiae of 15 rabbits in such a way that 3 to 4 of the coronal threads were left exposed on one side of each implant. Subsequently, test implants received an e-PTFE membrane for defect coverage, whereas control implants were not covered. Animals were sacrificed after 6, 9, and 15 weeks, respectively. A significantly better ($P < .0001$) bone gain of 99.5% was found for test implants, compared to 66.4% for control implants irrespective of the time of sacrifice. However, no data were reported on direct bone-to-implant contact within the regenerated area.

Since that pioneer study, a multitude of animal studies have evaluated different histometric and histomorphometric parameters of peri-implant bone regeneration. Most of these studies have examined the effect of a non-resorbable, bioinert e-PTFE membrane on bone regeneration around partially exposed implant surfaces with simultaneous implant placement. Though it was demonstrated in several experimental studies that the bone-promoting effect of this technique and indication was reproducible, complications such as membrane exposure or membrane collapse were also often reported.¹⁵⁻¹⁸ Recently, experimental studies evaluating bone-promotion techniques with simultaneous implant placement have focused on bioabsorbable membranes,¹⁹⁻²² on new bone grafting materials,²³⁻²⁵ or even on the use of biologic mediators.²⁶

The present study investigated the osseointegration of non-submerged dental implants placed into previously augmented sites. Four grafting techniques employing 3 different bone grafting materials were tested in the canine mandible and compared to native bone. Irrespective of the type of grafting technique, all implants achieved osseointegration during a healing period of 2 months. All implants demonstrated intimate contact of the rough and microporous TPS surface with bone, which in turn showed remodeling and osteons adjacent to the implant surface. Within a specific site, BIC on the buccal aspect (ie, the implant surface contacting regenerated bone) was statistically similar to the BIC on the lingual aspect (ie, the implant surface in contact with the non-regenerated lingual bone) among the 4 tested grafting conditions. Also, no difference was found in comparison to control implants placed in native bone.

In another canine study, Berglundh and Lindhe²⁷ reported lower BIC for implants placed in a staged approach compared to the present study. After extractions in that study, defects in test sites were filled with a demineralized deproteinized bovine bone material; however, no membrane was applied. Control sites were not filled and were left to spon-

aneous healing with a blood clot. Three months later, nonsubmerged implants with a TPS surface were placed (8×3.3-mm ITI dental implants). Following a healing period of 4 months, bone-to-implant contact measured along the entire TPS surface was 44.1% for test implants and 45.8% for control implants. The smaller BIC percentage in that study compared to this study may have resulted from the possibility that the smaller-diameter implants may not have engaged the buccal and lingual cortices and may have contacted only cancellous bone within the previous alveoli.

Bone-to-implant contact may differ when implants are placed in a staged approach compared to a simultaneous approach. The reasons for this are not known but may be related to the number of times the bone is stimulated.²⁸ For instance, implant placement in a staged approach following an osteopromotion procedure stimulates bone formation at 2 separate timepoints. In contrast, a single activation of bone formation occurs when an implant is placed concomitantly with the osteopromotion procedure. The present study had a triple activation of bone formation, since tooth removal, ridge augmentation, and implant placement were all performed at separate timepoints. In addition, the implants immediately had intimate contact with both previously regenerated and native bone.

Few experimental studies have examined the behavior of regenerated bone around implants prior to loading. Rasmussen and associates²⁹ investigated changes in augmented bone after membrane removal around unloaded dental implants placed in the tibial metaphysis of rabbits. Membranes were removed after 8 weeks of healing, and the implants were followed for 16 more weeks. They reported substantial morphologic changes in membrane-protected newly formed bone. However, fewer dimensional changes were observed for the bone formed adjacent to the implant body compared to bone regenerated at distant areas, indicating that a solid surface may have a stabilizing effect on newly formed bone. Because that study was performed in long bones, it was not known whether a similar finding would occur in jawbone. The present study, however, has demonstrated such a phenomenon. Regenerated bone in direct contact with the buccal implant surface was consistently located more coronally than regenerated bone away from the implant surface. This was observed particularly in "DFDBA + membrane" sites, which had the most coronal fBIC (mean = 3.80 mm). In these sites, the thinnest buccal bone width was found (mean HBW = 0.32 mm). Bone resorption is thought to occur if a critical thickness of bone is not maintained. In the present

study, only “autograft + membrane,” “TCP + membrane,” and control sites demonstrated a mean buccal HBW greater than 1 mm, whereas lingual mean HBWs for all sites were greater than 2.1 mm irrespective of treatment.

Implant position and angulation in the bone may also affect the level of the fBIC, as well as the buccal and lingual width of the crestal bone around implants. However, to the authors' knowledge, no study has ever investigated such a possible correlation. It must be emphasized that no attempt was made to standardize the angulation and position of implants upon placement in the present study. It was rather a post-experimental observation that the long axis of the placed implants seldom matched the long axis of the alveolar ridge. The inadvertent buccal inclination of many of the evaluated implants may be explained by 2 reasons: (1) placement of implants in intubated dogs lying on their side makes tilting of drills toward the surgeon more likely, and (2) augmentation sites, particularly those with a granular bone grafting material, may demonstrate low resistance on the buccal aspect, facilitating swerving of drills.

Maintenance of a reconstructed alveolar crest is important for the final outcome of any osteopromotion technique. A bone grafting material or a mechanical support are measures attempting to prevent membrane collapse into the defect.³⁰ In the present study, the membranes covering the sites grafted with TCP- and DFDBA-particles had been supported by a tent pole-like screw anchored in the middle of the defect into the lingual cortex. Nevertheless, partial membrane collapse was observed at surgery 2 around the supporting screw, compromising the amount of the localized ridge augmentation. Possible explanations for this finding might be pressure of the soft tissue onto the membrane during the initial healing period and displacement of loose grafting particles prior to their osseous integration. In contrast to particulate grafting materials, corticocancellous block grafts are rigid and provide better biomechanical stability. However, without a barrier membrane or titanium mesh, block grafts may also undergo considerable resorption.^{31–33} The beneficial effect of placing a membrane in conjunction with block autografts was also demonstrated in the present study. Sites treated with membrane-protected autografts showed better mean buccal fBIC and HBW measurements than sites treated with autografts alone. Also, the original contour was more ideally preserved in membrane-protected autografts. The same findings were shown in a pilot study evaluating different bone fillers with or without membrane application for lateral ridge augmentation.¹¹

CONCLUSIONS

The findings in the present study support the following conclusions:

1. Non-submerged implants with a rough titanium surface (TPS) placed into regenerated bone obtained a high percentage of bone-to-implant contact, irrespective of which of 4 different tested grafting techniques was used.
2. No statistically significant differences were calculated for any of the 3 histometrically evaluated parameters (fBIC, HBW, and BIC) on the buccal implant aspect facing regenerated bone among the 4 different grafting conditions and compared to native bone.
3. Based on the BIC results, regeneration of bone using the presented techniques of lateral ridge augmentation resulted in a similar proportion of direct connection between the implant surface and the bone.

ACKNOWLEDGMENTS

The authors gratefully acknowledge the assistance of Britt Hoffmann, Department of Oral Surgery, University of Berne; and Sonja A. Bustamante, HT, and Richard J. Haines, DVM, Clinical Veterinarian, and Dr Haines' team, Laboratory Animal Resources, all at UTHSCSA. We are also thankful to John D. Schoolfield, Mathematical Consultant at UTHSCSA, for the statistical analysis. The study was funded by grants from the ITI Foundation, Waldenburg, Switzerland; the Foundation for Dental Research and Education (FDR), Waldenburg, Switzerland; and the Dr H C Robert Mathys Foundation, Bettlach, Switzerland.

REFERENCES

1. Buser D, Dula K, Belser U, Hirt HP, Berthold H. Localized ridge augmentation using guided bone regeneration. I. Surgical procedure in the maxilla. *Int J Periodontics Restorative Dent* 1993;13:29–45.
2. Nevins M, Mellonig JT. The advantages of localized ridge augmentations prior to implant placement: A staged event. *Int J Periodontics Restorative Dent* 1994;14:97–111.
3. Weber HP, Fiorellini JP, Buser D. Hard tissue augmentation for the placement of anterior dental implants. *Compend Contin Educ Dent* 1997;18:779–791.
4. Buser D, Dula K, Lang NP, Nyman S. Long-term stability of osseointegrated implants in bone regenerated with the membrane technique. *Clin Oral Implants Res* 1996;7:175–183.
5. Fugazzotto PA. Report of 302 consecutive ridge augmentation procedures: Technical considerations and clinical results. *Int J Oral Maxillofac Implants* 1998;13:358–368.
6. Nevins M, Mellonig JT, Clem DS, Reiser GM, Buser D. Implants in regenerated bone: Long-term survival. *Int J Periodontics Restorative Dent* 1998;18:35–45.

7. von Arx T, Wallkamm B, Hardt N. Localized ridge augmentation using a micro titanium mesh: A report on 27 implants followed from 1 to 3 years after functional loading. *Clin Oral Implants Res* 1998;9:123-130.
8. Buser D, Ruskin J, Higginbottom F, Hardwick R, Dahlin C, Schenk RK. Osseointegration of titanium implants in bone regenerated in membrane-protected defects: A histologic study in the canine mandible. *Int J Oral Maxillofac Implants* 1995;10:666-681.
9. Mellonig JT, Nevins M. Guided bone regeneration of bone defects associated with implants: An evidence-based outcome assessment. *Int J Periodontics Restorative Dent* 1995; 15:168-185.
10. Buser D, Hoffmann B, Bernard JP, Lussi A, Mettler D, Schenk RK. Evaluation of filling materials in membrane-protected bone defects. A comparative histomorphometric study in the mandible of miniature pigs. *Clin Oral Implants Res* 1998;9:137-150.
11. von Arx T, Cochran DL, Hermann JS, Schenk RK, Buser D. Lateral ridge augmentation using different bone fillers and barrier membrane application. A histologic and histomorphometric pilot study in the canine mandible. *Clin Oral Implants Res* (in press).
12. Schenk RK, Olah AJ, Hermann W. Preparation of calcified tissue for light microscopy. In: Dickson GR (ed). *Methods of Calcified Tissue Preparation*, ed 1. Amsterdam: Elsevier Science Publishers, 1984:1-56.
13. Brånemark P-I, Hansson BO, Adell R, et al. Osseointegrated implants in the treatment of the edentulous jaw. Experience from a 10-year period. *Scand J Plast Reconstr Surg Hand Surg* 1977;11(suppl 16).
14. Dahlin C, Sennerby L, Lekholm U, Lindhe A, Nyman S. Generation of new bone around titanium implants using a membrane technique: An experimental study in rabbits. *Int J Oral Maxillofac Implants* 1989;4:19-25.
15. Becker W, Becker BE, Handelsman M, et al. Bone formation at dehiscenced dental implant sites treated with implant augmentation material: A pilot study in dogs. *Int J Periodontics Restorative Dent* 1990;10:93-101.
16. Arora BK, Worley CM, Guttu RL, Laskin DM. Bone formation over partially exposed implants using guided tissue generation. *J Oral Maxillofac Surg* 1992;50:1060-1065.
17. Gotfredsen K, Nimb L, Buser D, Hjørting-Hansen E. Evaluation of guided bone generation around implants placed into fresh extraction sockets: An experimental study in dogs. *J Oral Maxillofac Surg* 1993;51:879-884.
18. Fiorellini JP, Engebretson SP, Donath K, Weber HP. Guided bone regeneration utilizing expanded polytetrafluoroethylene membranes in combination with submerged and nonsubmerged dental implants in beagle dogs. *J Periodontol* 1998;69:528-535.
19. Lundgren AK, Sennerby L, Lundgren D, Taylor A, Gottlow J, Nyman S. Bone augmentation at titanium implants using autologous bone grafts and a bioresorbable barrier. An experimental study in the rabbit tibia. *Clin Oral Implants Res* 1997;8:82-89.
20. Hurzeler MB, Quinones CR, Huttmacher D, Schupbach P. Guided bone regeneration around dental implants in the atrophic alveolar ridge using a resorbable barrier. An experimental study in the monkey. *Clin Oral Implants Res* 1997;8: 323-331.
21. Mellonig JT, Nevins M, Sanchez R. Evaluation of a bioabsorbable physical barrier for guided bone regeneration. Part I. Material alone. *Int J Periodontics Restorative Dent* 1998; 18:129-137.
22. Mellonig JT, Nevins M, Sanchez R. Evaluation of a bioabsorbable physical barrier for guided bone regeneration. Part II. Material and a bone replacement graft. *Int J Periodontics Restorative Dent* 1998;18:139-149.
23. Hammerle CHF, Chiantella GC, Karring T, Lang NP. The effect of a deproteinized bovine bone mineral on bone regeneration around titanium dental implants. *Clin Oral Implants Res* 1998;9:151-162.
24. Kohal RJ, Mellas P, Hürzeler MB, Trejo PM, Morrison E, Caffesse RG. The effects of guided bone regeneration and grafting on implants placed into immediate extraction sockets. An experimental study in dogs. *J Periodontol* 1998;69: 927-937.
25. Hall EE, Meffert RM, Hermann JS, Mellonig JT, Cochran DL. Comparison of bioactive glass to demineralized freeze-dried bone allograft in the treatment of intrabony defects around implants in the canine mandible. *J Periodontol* 1999; 70:526-535.
26. Cochran DL, Schenk RK, Buser D, Wozney DM, Jones AA. Recombinant human bone morphogenetic protein-2 stimulation of bone formation around endosseous dental implants. *J Periodontol* 1999;70:139-150.
27. Berglundh T, Lindhe J. Healing around implants placed in bone defects treated with Bio-Oss. An experimental study in the dog. *Clin Oral Implants Res* 1997;8:117-124.
28. Schenk RK. Promotion of bone regeneration. In: Buser D, Dahlin C, Schenk RK (eds). *Guided Bone Regeneration in Implant Dentistry*, ed 1. Chicago: Quintessence, 1994:72-96.
29. Rasmussen L, Sennerby L, Lundgren D, Nyman S. Morphological and dimensional changes after barrier removal in bone formed beyond the skeletal borders at titanium implants. A kinetic study in the rabbit tibia. *Clin Oral Implants Res* 1997;8:103-116.
30. Buser D, Dula K, Hirt HP, Schenk RK. Lateral ridge augmentation using autografts and barrier membranes: A clinical study with 40 partially edentulous patients. *J Oral Maxillofac Surg* 1996;54:420-432.
31. von Arx T, Hardt N, Walikamm B. The TIME technique: A new method for localized alveolar ridge augmentation prior to placement of dental implants. *Int J Oral Maxillofac Implants* 1996;11:387-394.
32. Widmark G, Andersson B, Ivanoff CJ. Mandibular bone graft in the anterior maxilla for single-tooth implants. Presentation of a surgical method. *Int J Oral Maxillofac Surg* 1997;26:106-109.
33. Widmark G, Andersson B, Andrup B, Carlsson GE, Ivanoff CJ, Lindvall AM. Rehabilitation of patients with severely resorbed maxillae by means of implants with or without bone grafts. A 1-year follow-up study. *Int J Oral Maxillofac Implants* 1998;13:474-482.